

Urologic Emergencies



Adam E. Ludvigson, MD^a, Lisa T. Beaulé, MD^{b,*}

KEYWORDS

- Urologic emergencies • Testicular torsion • Acute urinary retention • Paraphimosis
- Obstructed pyonephrosis • Fournier gangrene • Ischemic priapism

KEY POINTS

- Urologic emergencies must be identified in a timely fashion.
- Optimal management strategy should be determined when urologic services are not available.
- An understanding of the pathophysiology of acute urologic emergencies is crucial.

ACUTE URINARY RETENTION

Overview

Urinary retention is one of the most common medical problems encountered in clinical practice, and most health care professionals will be involved in its treatment at one time or another. Acute and chronic urinary retention, however, are different clinical entities that demand differing courses of treatment. Acute urinary retention (AUR) requires prompt recognition and reversal by medical staff of all levels, whereas chronic urinary retention is by definition a less immediately severe condition.

Causes/Pathophysiology

Stated broadly, AUR is the sudden inability of the bladder to empty itself of urine, whether due to a blocked outflow tract or intrinsic abnormality of the bladder (or both). Using this definition, AUR can be divided into obstructive and dysfunctional categories.

In all obstructive causes of AUR, the underlying cause of retention is the physical obstruction of the outflow tract, that is, the bladder neck or urethra. This obstruction is most commonly due to benign prostatic hyperplasia (BPH), a common condition among older men. As men age, the central zone of the prostate (the area lining the urethra) undergoes a slow but steady enlargement, causing progressive narrowing of the urethra. Because the onset is insidious, a patient may chronically retain increasing

There are no disclosures to report.

^a Division of Urology, Maine Medical Center, 100 Brickhill Ave., South Portland, Maine 04106, USA; ^b Division of Urology, Maine Medical Center, Tufts University School of Medicine, 100 Brickhill Ave., South Portland, Maine 04106, USA

* Corresponding author.

E-mail address: beaul@mmc.org

Surg Clin N Am 96 (2016) 407–424

<http://dx.doi.org/10.1016/j.suc.2016.02.001>

surgical.theclinics.com

0039-6109/16/\$ – see front matter © 2016 Elsevier Inc. All rights reserved.

amounts of urine for many years before a precipitating event suddenly leads to the complete inability to urinate. The inciting event can be infection, medications, recent trauma (such as urethral catheter insertion), locoregional anesthesia, or idiopathic. Once in retention, the bladder becomes over-distended such that the sarcomeres of the smooth muscle cells in the bladder wall cannot properly engage one another, and the contractile force of the bladder is diminished, worsening the problem.

Any other process that causes urethral narrowing can produce difficulty emptying the bladder, such as urethral stricture or bladder neck contracture. Urethral strictures and bladder neck contractures are typically sequelae of urologic procedures, such as traumatic urethral instrumentation or previous prostate surgery, straddle injuries, or sexually transmitted infection. However, they may be congenital, and patients may not be aware of them at the time of presentation.

Urine outflow can also be blocked by a foreign object. The most common cause is a blood clot formed within the bladder of a patient with significant gross hematuria, whether from bladder cancer, traumatic urethral catheter insertion, or recent surgery. Any recent urologic surgery or procedure is a risk factor for hematuria. Other foreign objects can block urine outflow as well, such as bladder or kidney stones, or material left over from urologic procedures that involve resection of tissue.

In addition, intrinsic bladder dysfunction can produce urinary retention every bit as acutely as a physical blockage and can worsen any underlying low-level physical blockage as well. Common causes for bladder dysfunction include medications (anticholinergics in particular), nerve damage due to diabetes or congenital defect, and, as previously discussed, simple over-distention due to other causes¹ (**Box 1**).

Diagnosis

The diagnosis of AUR is straightforward in theory, but occasionally challenging in practice. Patients with AUR will usually complain of suprapubic pain/pressure, urinary frequency, urgency, voiding in small amounts, bladder spasms, penile pain, and inability to urinate, but some patients may be unable to relate their symptoms, or may actually be asymptomatic. If patients have diminished bladder sensation, their symptoms can be nonspecific: these patients often present with only shortness of breath and diaphoresis.

A bladder scanner may be used to quantify the amount of urine present in the bladder to aid diagnosis, but the results should be interpreted carefully. The bladder scanner is frequently fooled by the presence of intra-abdominal fluid, oddly shaped

Box 1

Common drugs leading to bladder dysfunction

Benadryl (diphenhydramine)
 General/locoregional anesthetics
 Opioids
 Alcohol intoxication
 Antidepressants (tricyclics especially)
 Decongestants
 Muscle relaxants

Adapted from Vilke GM, Ufberg JW, Harrigan RA, et al. Evaluation and treatment of acute urinary retention. *J Emerg Med* 2008;35(2):194.

bladders, and recent surgeries causing inflammation in the area, which leads to estimates of urine that are too high or too low. The bladder scanner should never be used to follow urine output if the patient's fluid status is in doubt. Absent any indications that the number may be inaccurate, and assuming the patient is not chronically retentive of large volumes of urine, a bladder scanner reading of 400 mL or higher should prompt catheterization.

If a dedicated bladder scanner is not available, simple ultrasonography can be used to directly visualize the bladder. Physical examination will frequently reveal a palpable bladder above the pubic bone as well as suprapubic tenderness. A digital rectal examination can identify prostatic enlargement or tenderness. A basic metabolic panel (BMP) should be obtained to rule out electrolyte disturbances, and a complete blood count (CBC) should be obtained if hematuria is the presenting complaint, because patients can lose a surprising amount of blood via this mechanism.

Patient history should focus on the length of time since the last void, the color and consistency of the urine, and baseline voiding characteristics. The clinician should ascertain whether the patient has trouble emptying their bladder normally and inquire specifically as to any recent or past urologic interventions. A suprapubic or midline abdominal incision or radiation tattoos may be associated with prior prostate or bladder surgery or radiation therapy; in this instance, a smaller catheter should be considered, as the cause is less likely to be BPH and more likely to be urethral stricture of bladder neck contracture. Special attention should be paid to any scrotal prosthesis that may represent a pump for an artificial urinary sphincter (AUS). In this case, urologic consultation should always be obtained before placement of a urethral catheter to deactivate the AUS in order to avoid erosion and damage to the device (**Box 2; Fig. 1**).

Treatment

The initial management of urinary retention is always drainage of the bladder. In the vast majority of cases, this is accomplished by the insertion of a urethral catheter. Any clinician who is treating a patient with AUR should first attempt placement of a urethral catheter, unless there is some obvious anatomic complication that necessitates the involvement of Urology. In general, if the urethral meatus is visible, urethral placement should be attempted through it at least once.²

Urethral catheter placement technique

The first consideration is the size of the catheter, measured in the French catheter scale. A catheter's size in French is exactly 3 times its outer diameter in millimeters (therefore, its circumference is slightly larger, because the circumference is the diameter times pi). For example, an 18-French catheter has an outer diameter of 6 mm. Outer diameter is stressed here to emphasize that a regular and 3-way 20-French

Box 2

Workup of acute urinary retention

- Review of surgical history (especially urologic)
- Assess baseline voiding function
- Bladder scan
- Basic metabolic panel (BMP)
- Complete blood count (CBC) if hematuria
- Digital rectal examination (DRE)

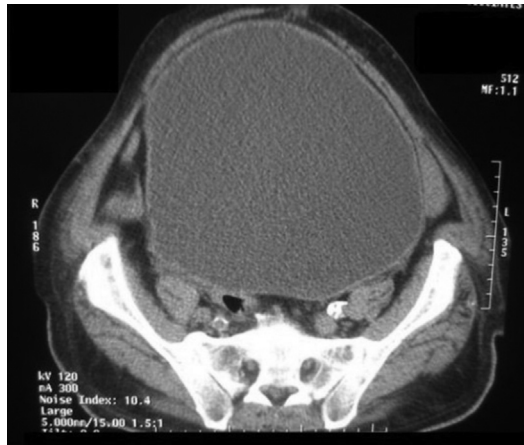

Fig. 1. CT scan: severely distended urinary bladder secondary to urinary retention. (From Sharma A, Naraynsingh V. Distended bladder presenting with constipation and venous obstruction: a case report. *J Med Case Rep* 2012;6:34.)

catheter will have different internal diameters, because a 3-way catheter must incorporate 3 internal channels into the same outer tube.

When trying to pass a urethral catheter through a large prostate, a larger catheter should be used, rather than a smaller one. Many insertion attempts fail because a small catheter was used, which lacks the stiffness necessary to push past the lobes of an enlarged prostate. A reasonable starting point is 18 French. If resistance is consistently encountered, further attempts should be abandoned to avoid the possibility of creating a false passage that will hinder further attempts. A Coudé (French for “elbow”) catheter, a catheter with an upwards bend at the tip, can and should be used if BPH is suspected. The catheter is inserted perpendicular to the patient as with a normal catheter placement and then lowered toward the bed when resistance is encountered at the prostate, allowing the bent tip to negotiate the enlarged prostate (**Box 3; Fig. 2**).

If urethral catheter placement is not possible, a flexible cystoscope can be used to gain access to the bladder under direct visualization in order to place a wire for guidance. In some cases, the wire can be placed blindly, although this should be done with extreme caution. The urethral stricture can then be serially dilated with sounds as needed to facilitate urethral catheter placement. If all else fails, the bladder can be drained directly via suprapubic decompression or formal suprapubic tube placement. Ultrasound guidance, which is available in most emergency departments, can be helpful and safer than blind placement.

If the patient is in clot retention (that is, blood clots are blocking urine flow), the best catheter to place is a large-bore single-channel catheter, such as a silastic or 6-eye

Box 3

Common catheter choices

BPH: 18-French Coudé catheter

Clot retention: 22- to 24-French silastic catheter, 22-French 6-eye if unavailable

Continuous bladder irrigation: 20- to 24-French 3-way catheter

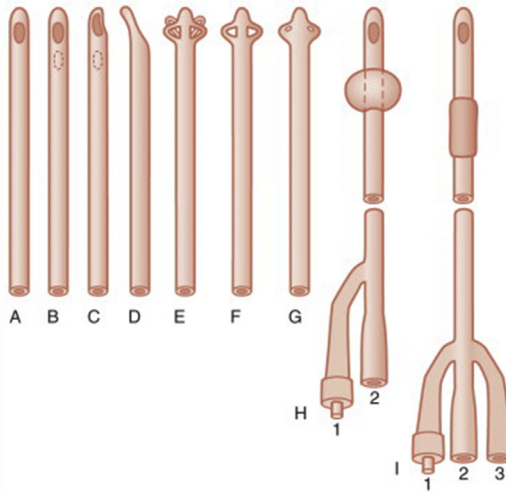


Fig. 2. Large-diameter catheters. *A*, Conical-tip urethral catheter. *B*, Robinson urethral catheter. *C*, Whistle-tip urethral catheter. *D*, Coudé hollow olive-tip catheter. *E*, Malecot self-retaining, four-wing urethral catheter. *F*, Malecot self-retaining, two-wing urethral catheter. *G*, Pezzer self-retaining drain, open-end head, used for cystostomy drainage. *H*, Foley-type balloon catheter. *I*, Foley-type, three-way balloon catheter, one limb of distal end for balloon inflation (1), one for drainage (2), and one to infuse irrigating solution to prevent clot formation within the bladder (3). (From Thompson JR. Bladder catheterization. In: Stehr W, editor. The Mont Reid surgical handbook. 6th edition. Philadelphia: Saunders; 2008. p. 839–48; with permission.)

catheter, because the patient will need his or her bladder irrigated thoroughly to remove the clots. Although a 3-way catheter will eventually need to be placed to allow continuous bladder irrigation to stop more clots from forming, this catheter cannot be hand-irrigated well and should only be placed once clots have been evacuated from the bladder, not before.

FOURIER GANGRENE

Overview

Fournier gangrene is a term given to a severe and rapidly progressive necrotizing infection of the skin and soft tissue of the perineal region, including the genitalia. It is one of the few true urologic emergencies and prompt recognition is critical in order to save as much tissue as possible (as well as the patient's life). Morbidity is significant; however, in the modern era with rapid surgical intervention and broad-spectrum antibiotics, the mortality has decreased somewhat. Treatment remains invariably morbid, and a multidisciplinary approach is required to manage the myriad clinical challenges that arise both during and after the acute treatment period.

Causes/Pathophysiology

The exact cause of Fournier gangrene is not known presently, although most patients have comorbid factors that predispose them to infection and skin breakdown (eg, obesity, diabetes, immune compromise, or perirectal abscess). Bacterial isolates from patients frequently reveal a polymicrobial milieu involving both anaerobic and aerobic bacteria. A common event to all cases appears to be bacterial access to

the deep fascial planes, whereby rapid necrosis of tissue causes an ideal anaerobic environment for proliferation of still more bacteria. Once established, the infection spreads very rapidly, due to the causative organisms' secretion of various tissue toxins and virulence factors. Mortality varies according to numerous factors and has been associated most closely with hypertension, congestive heart failure, renal failure, and coagulopathy.³ The same study reported an overall mortality of 7.5%, and centers with experience in treating this condition have been shown to have significantly improved outcomes (Box 4).

Diagnosis

Patients will usually present with complaints of severe perineal pain. As with necrotizing fasciitis, this pain is out of proportion to any external signs. Erythema is often present, progressing rapidly to dark or black necrosis and sloughing of tissue. Patients may report tightness and discomfort in the perineal/genital region before the onset of pain. Clinical suspicion should remain high for patients with the appropriate risk factors who exhibit these symptoms, especially given the dramatically high rate of progression once an infection begins. Crepitus, or a computed tomographic (CT) scan finding of subcutaneous air, is pathognomonic, although operative management should under no circumstances be delayed for definitive imaging. Patients may become hemodynamically unstable very quickly as tissue death accelerates (Figs. 3–5).

The use of serum markers of infection is usually low-yield, because the disease invariably declares itself very rapidly. Electrolytes should by all means be monitored closely, but these tend to serve as a guide for the management of severe sepsis as one would for any patient and do not exhibit derangements specific to Fournier.

Treatment

The first step of treatment is initiation of broad-spectrum antibiotics, chosen according to the hospital's antibiogram. However, antibiotics only serve to halt the spread of systemic illness. The only definitive treatment option for Fournier gangrene is swift and aggressive debridement of all affected tissue. Tissue is excised sharply until bleeding is encountered; this is usually the indication that healthy, viable tissue has been reached. Tissue Gram stain and culture can be helpful in directing ongoing antimicrobial treatment. Hemostasis can be achieved via liberal use of cautery, tying off larger vessels as necessary. In men, the scrotal skin is frequently involved, and at times almost none of it can be saved—however, the testicles are rarely involved and are often left exposed at the conclusion of debridement. Testicular thigh pouches can be created in subsequent procedures to maintain the testicles and to facilitate dressing changes, but wet-to-dry packing is all that is required to protect them in the short term.

Box 4 Risk factors for Fournier gangrene

- Diabetes
- Immunosuppression
- Obesity
- Pre-existing perineal soft tissue infection
- Liver disease

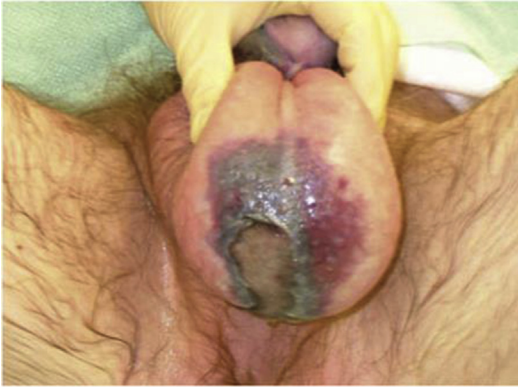

Fig. 3. Fournier gangrene demonstrating dark, necrotic skin and soft tissue involving the right hemiscrotum and extending into the left hemiscrotum and perineum. (From Kessler CS, Bauml J. Non-traumatic urologic emergencies in men: a clinical review. *West J Emerg Med* 2009;10(4):286.)

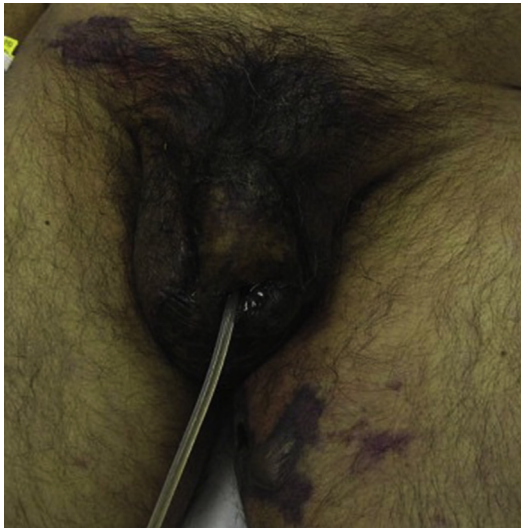


Fig. 4. Fournier gangrene demonstrating expanding necrotic tissue involving the genitalia, right inguinal region, and left inner thigh. (From Kim DJ, Kendall JL. Fournier's gangrene and its characteristic ultrasound findings. *J Emerg Med* 2013;44(1):e100; with permission.)

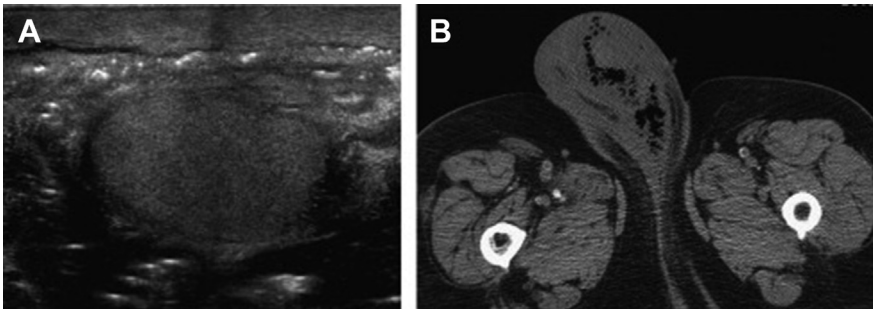


Fig. 5. Subcutaneous gas in Fournier gangrene on scrotal ultrasound (A) and CT scan of scrotum (B). (From Mirochnik B, Bhargava P, Dighe MK, et al. Ultrasound evaluation of scrotal pathology. *Radiol Clin North Am* 2012;50(2):319, vi; with permission.)

If enough penile tissue remains, a urethral catheter is left in place to prevent urine drainage onto open wounds. In some cases, it may be necessary to place a suprapubic tube to allow perineal and penile tissues to heal appropriately.

Under no circumstances should attempts be made to reconstruct a scrotum at the time of initial debridement, because the wound is still actively infected, and the patient is unlikely to tolerate lengthy surgery. Once the infection has been adequately treated and all necrotic tissue has been debrided, attention can be turned to reconstruction. Plastic surgery consultation is often useful, because muscle flap rotations are sometimes needed to fill in the large defects left after aggressive debridement.

Patients will almost invariably require treatment in an intensive care unit following surgery, because they are very often systemically ill—most deaths occur late in this postoperative period, not during the initial acute surgically managed phase.³

ISCHEMIC PRIAPISM

Overview

Priapism is an uncommon urologic emergency that presents as an unwanted erection that persists longer than 4 hours. This condition is subdivided into ischemic, or low-flow, priapism; and non-ischemic, or high-flow, priapism. Ischemic priapism is the focus of this section, because its treatment should be as urgent as possible to prevent possible long-term sequelae, whereas nonischemic priapism can be treated far less urgently and portends no loss of tissue or function. Although only male priapism will be discussed here, it is important to note that clitoral priapism can occur in very rare cases as well, due to the presence of erectile tissue.⁴

Causes/pathophysiology

An erection is produced by the corpora cavernosa, two tubelike structures that run the length of the shaft of the penis and project into the pelvis for anchoring purposes. Each corporal body consists of a spongy mass of highly vascularized tissue surrounded by a tough fibrous coating. During sexual arousal, the vessels feeding the corpora dilate under autonomic control, allowing more blood into the corpora; this in turn tamponades the outflow vessels. The result is that the spongy tissue within each corporal body expands against the inflexible fibrous sheath, producing rigidity. During detumescence, the inflow vessels constrict again, allowing a net amount of blood to leave the corpora, which reduces the tamponade of the outflow vessels, which allows more blood to leave, and so on.

However, if this process is interrupted, the corpora can enter a state of sustained engorgement that quickly becomes painful and begins to threaten tissue—it is essentially a compartment syndrome of the penis.⁵ The physiologic internal pressure of the corpora, in addition to preventing venous outflow, begins to impede inflow as well, leading to tissue ischemia and eventually necrosis. For this reason, any erection that has persisted longer than 4 hours should be dealt with promptly to prevent serious immediate or future complications.

This disruption is often related to medications, especially those with α -adrenergic effects. Oral erectile dysfunction agents are rarely implicated, and in fact, extremely high doses of these medications can be ingested without producing priapism.⁶ Blood disorders such as sickle cell anemia, which causes clogging of the outflow vessels and persistence of the erection, is a significant risk factor; this is in contrast to high-flow or nonischemic priapism, in which fistulization between arterial and venous systems within the penis produces erection through too-rapid inflow of arterial blood into the corpora. Although the erection is persistent, it is the result of an overabundance of well-oxygenated blood, and therefore, is neither painful nor an emergency (**Box 5**).

Box 5**Pharmacologic agents leading to ischemic priapism**

Vasoactive agents used for erectile dysfunction (eg, phentolamine, prostaglandin E1)

α -Blocking agents (eg, prazosin, terazosin, tamsulosin)

Hydroxyzine

Antidepressants and antipsychotics

Certain antihypertensives (eg, hydralazine, propranolol, labetalol)

Cocaine

Ethanol

Adapted from Anele UA, Le BV, Resar LM, et al. How I treat priapism. Blood 2015;125(23):3553.

The incidence of priapism has been shown to be bimodal, with most patients presenting between 5 to 10 and 20 to 50 years of age. The incidence is much higher in those affected by sickle cell anemia, for previously discussed reasons. For this patient population, lifetime incidence can reach as high as 42%, with significant clinical sequelae.⁷

Diagnosis

The patient should be asked if he has a history of priapism, sickle cell disease, or trauma to the penis. An adequate history of present illness (HPI) is important as the length of time the erection has persisted is a critical piece of information. High-flow priapism will present as a persistent erection that is not rigid and is not painful. Patients will frequently present very late in the time course of this process because of this characteristic lack of pain.

The diagnosis of ischemic priapism can usually be made clinically. Patients almost always present with a very rigid, painful erection that has persisted much longer than 4 hours (acute embarrassment often prevents a more timely visit to the hospital). The glans penis is usually not engorged. Skin changes, if present, are an ominous sign.

Even if clinical suspicion is high, a penile blood gas should be drawn to ensure accurate diagnosis, because performing a procedure to reverse ischemic priapism carries certain risks and should never be undertaken for high-flow priapism. This procedure is performed by using a large-bore intravenous needle with an angiocatheter to access the corporal body (after the injection of local anesthesia) and gently draw off 5 to 10 mL of blood for analysis. Withdrawing too hard will collapse the surrounding veins and prevent aspiration. The angiocatheter should be left in place to assist with future irrigation. Blood gas analysis in ischemic priapism usually reveals acidosis, hypoxia, and hypercapnia; values consistent with arterial blood indicate high-flow priapism instead. Color Doppler ultrasonography can be used as well, although penile blood gas analysis is more common and is generally sufficient to make the diagnosis (Fig. 6).

Treatment

Treatment of ischemic priapism hinges on the removal of accumulated blood and clot from within the corpora, and reversal of the underlying cause. The mainstay of treatment in the emergency room is injection of an α -agonist agent, usually phenylephrine, to produce vasoconstriction of the inflow channels and allow blood to drain passively from the corpora. Sometimes, a single injection is sufficient to achieve detumescence; however, penile irrigation is often required in conjunction. This is accomplished by the

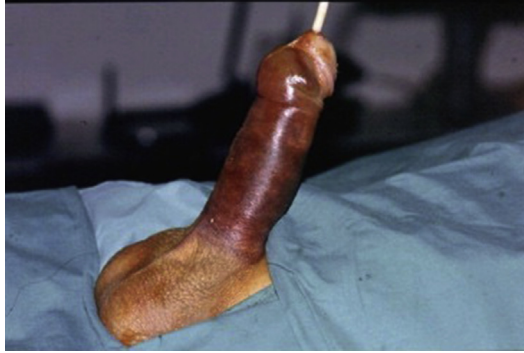

Fig. 6. Ischemic priapism. Ecchymosis (from attempted corporal injection of α -adrenergic agonist and aspiration) spares the glans penis. (From Ralph DJ, Garaffa G, Muneer A, et al. The immediate insertion of a penile prosthesis for acute ischaemic priapism. *Eur Urol* 2009;56(6):1035; with permission.)

placement of a single large-bore angiocatheter into the corpora to allow instillation and aspiration of saline solution. Placement of the angiocatheter is sufficient to correct the problem in most cases and rarely results in significant complications (aside from the complications inherent to the condition itself).

If priapistic episodes recur, the surgeon may elect to perform a shunting procedure to reduce the likelihood of future events. Shunt placement consists simply of creating a defect in the corpora, to improve the ability of blood to drain out. Shunts can be created between the corpora and either the glans, corpus spongiosum, or dorsal vein of the penis; they are preferably created as distally as possible to minimize the chances of erectile dysfunction. The preferred approach (for which multiple technical methods exist) is to insert a large-bore needle or scalpel through the glans into the tip of each of the corpora, creating a passage for blood into the tissue of the glans. Proximal shunts, if necessary, can be a morbid procedure⁸ (Fig. 7).

Long-term sequelae of recurrent or long-lasting priapistic episodes can include erectile dysfunction and scarring of the corpora, leading to penile curvature and

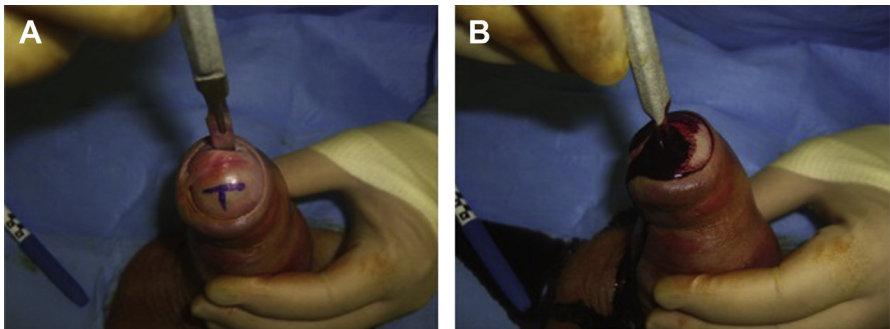


Fig. 7. T-shunt technique, a type of distal glandulocavernosal shunt, used to treat ischemic priapism that is unresponsive to corporal irrigation and injection. (A) Initial incision and markings, (B) completed procedure with brisk outflow of blood. (From Zacharakis E, Raheem AA, Freeman A, et al. The efficacy of the T-shunt procedure and intracavernous tunneling (snake maneuver) for refractory ischemic priapism. *J Urol* 2014;191(1):165; with permission.)

painful erections. These conditions can sometimes be corrected with future procedures, but return to normal function is far from assured.

OBSTRUCTIVE PYONEPHROSIS

Introduction

Although nephrolithiasis may be a painful condition, it rarely has the potential to cause serious medical harm. An obstructing, infected stone is another matter entirely, however. When infection develops behind an obstructing ureteral stone, the resulting illness can progress very rapidly, and for this reason, any patient with findings indicative of infection along with a kidney stone is treated promptly. The term obstructive pyonephrosis refers to a severe infection in a hydronephrotic or obstructed kidney that can lead to parenchymal destruction and loss of function; it is a more severe form of urosepsis and can be clinically indistinguishable.

Causes/Pathophysiology

Renal stones are present in many asymptomatic individuals, who may go their entire lives without having an attack of renal colic. Men tend to be affected more than women, and Caucasians more often than Hispanics, Asians, and African Americans, in descending order.⁹ Stone disease before age 20 is rare, with rates increasing until about the fourth to sixth decade of life.¹⁰

When a renal stone migrates into the ureter and causes obstruction, distention of the urothelial tract produces intense pain. Imaging will usually demonstrate hydronephrosis (dilation of the renal pelvis) in this case. If symptoms of flank pain are well-controlled on oral pain medications, and there is no associated infection, intractable emesis, or acute renal injury, then a trial of medical expulsive therapy is reasonable. This usually consists of hydration, an α -adrenergic blocker such as tamsulosin (Flomax), and narcotic pain control. Notably, there is increasing evidence that tamsulosin does not affect the success rate; however, it can improve ureteral pain.¹¹ If hydronephrosis is prolonged or severe, forniceal rupture can occur, which refers to extravasation of urine through the junction of the distal convoluted tubule and collecting duct of the kidney. This rupture is a normal physiologic pressure-release mechanism of the kidney. CT and ultrasound will show a perinephric fluid collection in this case, but no specific surgical intervention or antibiotics are required—treatment of the obstruction is sufficient, as discussed later¹² (Fig. 8).

When a stone obstructs the ureter, the buildup of urine behind it is susceptible to infection. If this occurs, the condition is known as obstructive pyonephrosis. Because infected urine can reflux directly into the bloodstream, patients can become septic very rapidly and require aggressive medical treatment. Drainage of the infected urine is imperative and is the mainstay of therapy, aside from appropriate antibiotic treatment.

Obstructive pyonephrosis can develop immediately in response to a stone, or it can develop as a chronic stone progresses to complete obstruction. The stone itself can serve as a nidus of infection. Infection with certain types of bacteria, particularly the *Proteus* genus, can lead to large and rapid accumulations of struvite stone, which can fill the entire collecting system and result in a “staghorn calculus.”

Diagnosis

A high degree of clinical suspicion is necessary to successfully treat this condition, because the patient's condition can worsen rapidly. Urinalysis (UA) should be obtained, and urine sent empirically for culture. The clinician should keep in mind that if the stone is completely obstructing, infected urine may not reach the bladder, and

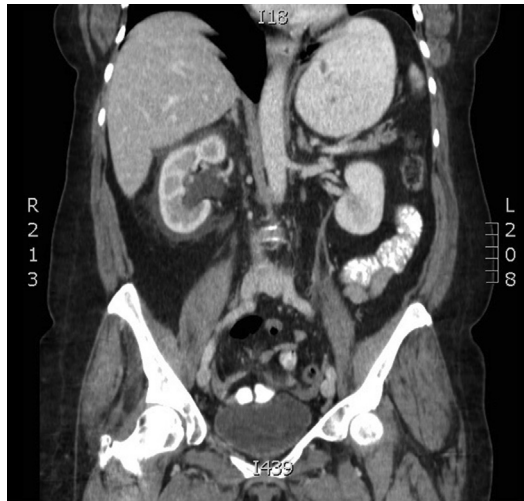

Fig. 8. Forniceal rupture with resulting fluid around right kidney associated with moderate hydronephrosis (personal patient).

a UA may therefore be normal. Negative test results should not delay treatment if the overall clinical picture suggests infection.

Imaging, whether CT or ultrasound, can help confirm the presence and severity of obstruction. Findings of hydronephrosis along with any findings suggestive of infection indicate urgent treatment. If obstruction due to kidney stone is suspected, no contrast is necessary for CT imaging; in fact, the lack of contrast enhances the ability to locate small stones.

Urinalysis interpretation

Interpreting UA results can be difficult at times. The most important test results when assessing a patient for infection in the setting of ureteral obstruction are leukocyte esterase, leukocytes, erythrocytes, nitrites, and bacteria. The presence of an indwelling ureteral stent can cloud the picture, because the stent itself will lead to hematuria and leukocytes in the urine. However, very high leukocyte esterase values (greater than 400), or the presence of nitrites, are rarely due to ureteral stents and should be treated as infection. As previously discussed, a negative UA should not delay treatment if infection is suspected on a clinical basis, because infected urine cannot drain to the bladder in the setting of complete obstruction.

Treatment

Prompt drainage is the only treatment option for obstructive pyonephrosis. Ideally, this can be accomplished by placing a ureteral stent, allowing infected urine to bypass the obstruction and temporizing the patient so that definitive treatment can be performed when infection has cleared. Kidney stones themselves are never treated or removed in the setting of infection, because the trauma to the urothelium can introduce bacteria into the bloodstream and worsen the patient's illness. During placement of the stent, urine can be obtained directly from the renal pelvis using a ureteral catheter, allowing an accurate urine culture to be sent. This ureteral catheter is especially helpful if the blockage is complete enough to prevent any infected urine from draining into the bladder.

If ureteral stenting is not possible or if the patient is showing signs of hemodynamic instability, a percutaneous nephrostomy tube should be placed by an Interventional

Radiologist or qualified Urologist without delay. Definitive treatment of the stone or other obstruction is then scheduled once the patient has recovered sufficiently.

PARAPHIMOSIS

Introduction

Paraphimosis is a painful and potentially serious condition characterized by the inability to return the foreskin to its normal position after it is retracted. It is usually seen in the hospital or chronic care setting following insertion of a urethral catheter into an uncircumcised male patient, during which the foreskin is retracted, allowing it to become entrapped in that position. If left untreated, paraphimosis has the potential to lead to tissue ischemia and necrosis—it should therefore be reduced as soon as possible.

Pathophysiology

A normal foreskin can be easily retracted back over the glans and returns to its normal position without difficulty. However, men may have a narrow band of tissue in the foreskin, called a phimotic ring, that can make retraction of the foreskin difficult. Men may not be aware of this condition, because they may seldom or never retract their foreskin completely, or it may not interfere sufficiently with their normal life to warrant correction. When the foreskin and its phimotic ring are retracted, a biological tourniquet is applied to the penis, causing edema to develop distally and making reduction of the foreskin increasingly difficult.¹³

Even an otherwise normal penis can develop enough edema in this state to cause paraphimosis. If a urinary catheter is in place providing an additional source of tension, or if injury, illness, fluid overload, or other medical conditions contribute to tissue edema, the problem is compounded.

Diagnosis

The diagnosis is usually made clinically, by physical examination, and by patient interview. Patients experience increasing pain as the tissue edema progresses and will be unable to reduce their foreskin. Patients with dementia may exhibit increasing agitation, prompting a physical examination and discovery of the problem. Sedated or noncommunicative patients, and those with neurologic conditions affecting their penile sensation, are particularly dangerous, because their condition may not be noted for some time. Over a period of hours, the affected tissue may become so edematous as to impede blood flow, leading to tissue loss and necrosis. If a urinary catheter is not present, patients may develop urinary retention as well (see [Fig. 8](#)).

Treatment

Several techniques exist for reducing paraphimosis; treatment is largely dictated by provider preference.^{5,14} The singular goal is to return the foreskin to its normal position and allow the patient's edema to recede, but frequently the anatomy is so distorted that even identification of foreskin, penis, and glans may be very difficult.

The authors' preferred method is to use gentle, constantly increasing pressure to gradually reduce edema enough to allow reduction of the foreskin. This method can be accomplished by simply squeezing the penis firmly until the foreskin can be retracted; alternatively, a simple compressive dressing can be applied for 10 to 15 minutes before reduction is attempted.¹⁵ Although one hand is applying steady pressure, the other should be used to gently squeeze and push the glans until it can be slid through the phimotic ring. In some cases, it may be easier to grasp the foreskin with both hands and use the thumbs to gently push the glans back through the

phimotic ring. If using a compressive dressing, the dressing can be removed and reapplied/tightened as necessary (Figs. 9–11).

The amount of pressure that can be brought to bear is often limited by the patient's discomfort, which can obviously be significant. Liberal use of narcotic pain medication and/or sedation may be necessary in severe cases. Topical anesthetics are often not effective, especially in adult patients, but ice can both provide analgesia and reduce edema. Patience is essential; an extended period of firm pressure is frequently required to reverse enough of the tissue edema to allow a successful reduction.

If all attempts to reduce the foreskin at the bedside fail, surgical intervention is indicated to prevent tissue loss. Circumcision is usually required in this instance, because the phimotic ring must be incised sharply to relieve the pressure.

TESTICULAR TORSION

Introduction

Testicular torsion is another of the true urologic emergencies, and prognosis is strongly determined by time to surgical intervention. The signs and symptoms of torsion are often unambiguous enough to establish the diagnosis without imaging or further tests, although these are certainly useful. However, no test should ever delay progression to the operating room if torsion is suspected. If recognized and treated in a prompt manner, torsion has a good prognosis, but the risk of sequelae is present regardless.

Pathophysiology

Testicular torsion cases peak between 12 and 16 years of age and are usually not associated with any significant past medical history; however, the presence of mass or malignancy on the cord, such as lymphoma, can predispose to torsion and compromise of vascular supply. Cold weather has been shown to increase incidence

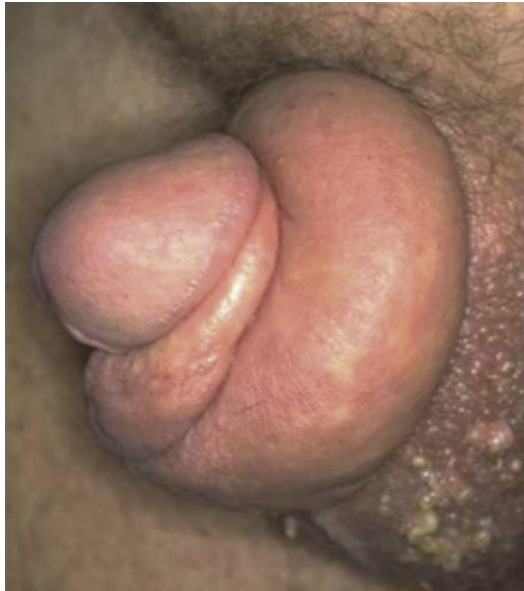

Fig. 9. Paraphimosis with severe edema of distal penile shaft and proximal tight phimotic ring (not seen in photo). (From Kessler CS, Bauml J. Non-traumatic urologic emergencies in men: a clinical review. *West J Emerg Med* 2009;10(4):283.)

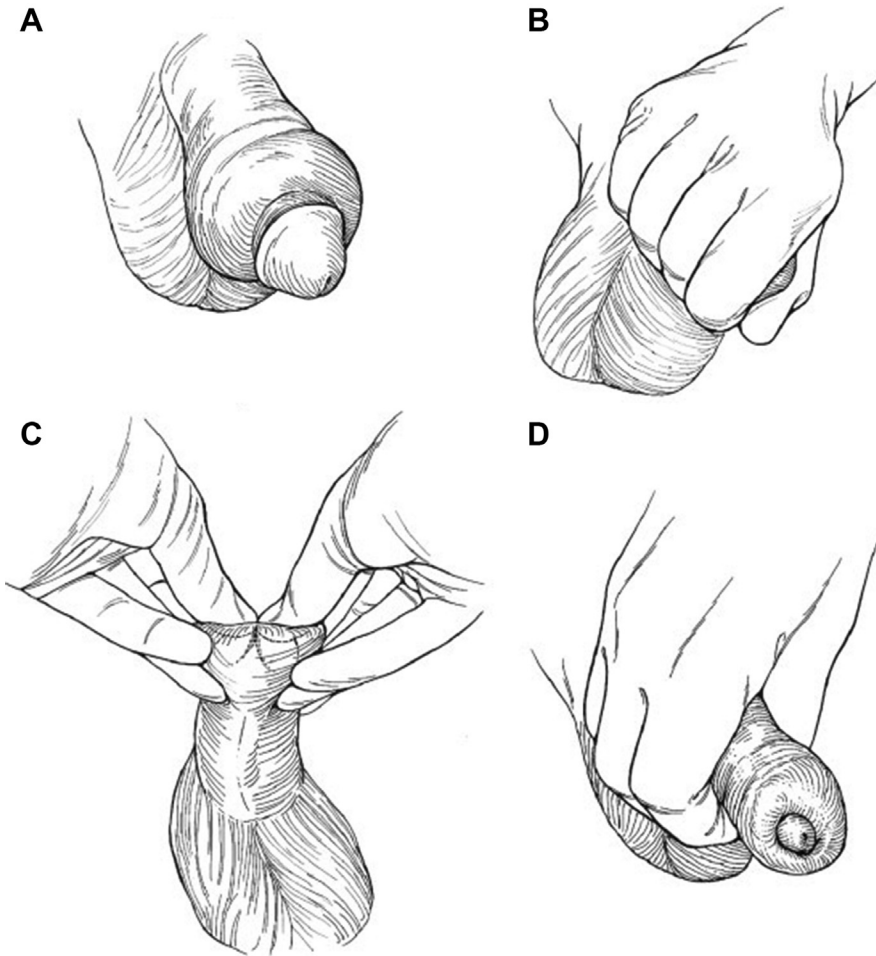


Fig. 10. Reduction of paraphimosis. Reduce edema of distal penile skin with manual compression to allow for replacement of distal penile preputial tissue over the glans penis. (A) Typical appearance of edematous penis with paraphimosis, (B) Firm manual pressure is applied to reduce edema, (C) Gentle counter-traction is applied to reduce foreskin, (D) Fully reduced paraphimosis with normal appearance of the penis. (From Vilke GM, Ufberg JW, Harrigan RA, et al. Evaluation and treatment of acute urinary retention. *J Emerg Med* 2008;35(2):196; with permission.)

somewhat, possibly due to the increased tone of dartos and cremasteric fibers, but this hypothesis is controversial.¹⁶

The most common type of testicular torsion encountered by surgeons is intravaginal torsion, wherein the testicle rotates within the tunica vaginalis. Intravaginal torsion is usually due to a congenital deformity known as bell clapper deformity.¹⁷ A normal testicle is prevented from rotating within the tunica vaginalis by a broad fusion of the parietal and visceral layers along the epididymis; however, in a significant portion of men, the area of fusion is smaller than usual, predisposing the testicle to rotation around this narrowed axis. The compression of arterial inflow to the testicle produces ischemia and intense pain.

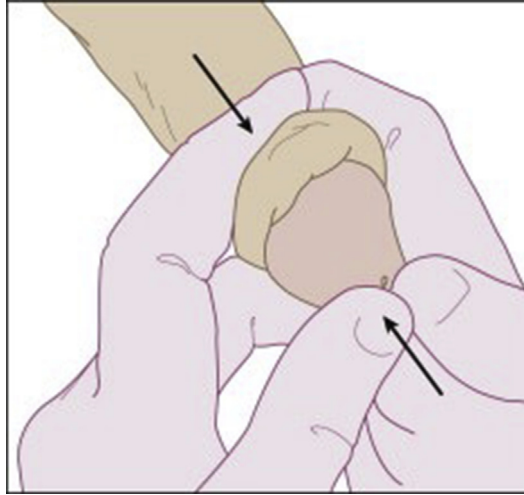


Fig. 11. Reduction of paraphimosis. (From Buttaravoli P. Chapter 81: Phimosis and paraphimosis. In: Buttaravoli P, editor. *Minor emergencies*. 2nd edition. Philadelphia: Mosby; 2007. p. 330; with permission.)

In comparison, extravaginal torsion, the twisting of the entire tunica vaginalis and spermatic cord, is primarily a perinatal event that presents as a painless, “vanishing” testicle in a newborn baby, or as a painless swollen and discolored hemiscrotum at birth. It is not a surgical emergency, because the window for salvage has almost always already passed by the time torsion is recognized.¹⁸

Diagnosis

The primary symptom of torsion is intense, sudden pain in the affected testicle. The severity of the pain means patients rarely delay seeking treatment, and therefore, often present well within the window of treatment. On physical examination, edema may be present, and the testicle may be observed or palpated (if allowed by the patient) higher than usual in the scrotum. The cremasteric reflex, upward movement of the affected testis elicited by lightly stroking the ipsilateral medial thigh, can be a helpful diagnostic test, because the presence of a functioning reflex is strongly correlated with intact blood flow. A UA may be obtained if the clinical picture is not completely indicative of torsion and there is suspicion for an infectious process — for example, if pain is relatively mild and urinary frequency, urinary urgency, or dysuria is present.

The mainstay of diagnostic tests for testicular torsion in recent years is the scrotal Doppler ultrasound, which can unequivocally demonstrate lack of blood flow to the testicle and confirm the diagnosis.¹⁹ The presence of blood flow should be compared with the contralateral testicle, because blood flow can be reduced rather than completely eliminated in some cases (Fig. 12).

It must be stressed: no diagnostic test should delay surgical exploration of the scrotum if torsion is strongly suspected. Urologic consultation should be obtained immediately at the same time confirmatory tests are being ordered. In an adolescent patient with severe, sudden-onset testicular pain, very little clinical information would be sufficient to warrant delaying surgery. If testicular torsion is recognized less than 6 hours after the onset of pain, the rate of testicular salvage is 95%. This rate drops to 80% after 7 hours, and 60% after 12 hours. After 12 hours, loss of the testicle is more likely than not.²⁰

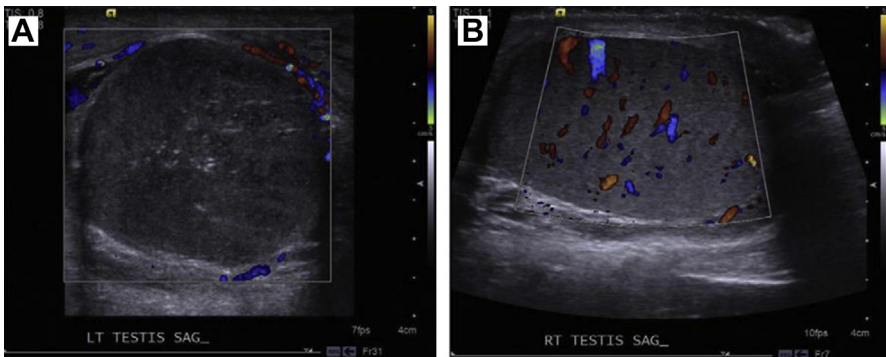


Fig. 12. Left-sided testicular torsion as demonstrated by absence of intratesticular Doppler flow on scrotal ultrasound. The right testis demonstrates normal blood flow. (A) Left testicle, which demonstrates no flow on Doppler ultrasound, (B) The normal contralateral testicle with intact bloodflow. (From Wang J-H. Testicular torsion. *Urological Science (Urol Sci)* 2012;23(3):85; with permission.)

Treatment

Manual detorsion can sometimes be accomplished, which may improve salvage rates until surgical exploration is available; again, this should never delay the operating room, as even a successfully detorsed testicle must be surgically explored.²⁰ The affected testicle should be rotated “away” from midline, as if one is opening a book, because approximately two-thirds of torsion cases prove to be rotated in a medial direction.^{19,20} Patients who are premedicated with narcotics will better tolerate bedside detorsion.

Surgical detorsion and orchiopexy are accomplished through a midline incision at the median raphe. After delivering the testicle, it is untwisted and observed closely to determine its viability. It is common to find an inflammatory hydrocele. If the testicle shows signs of adequate reperfusion (tissue viability, robust Doppler flow within the spermatic cord), it is sutured in a 3-point fixation to the scrotum with nonabsorbable suture to prevent future torsion events. If it appears necrotic or does not reperfuse after detorsion, orchiectomy is indicated. A concomitant contralateral orchiopexy should be performed to ensure no future events, especially if an orchiectomy was necessary.

Assuming all goes well in surgery, the long-term sequelae of testicular torsion is somewhat unclear. Oxidative stress has been shown to impair testicular functioning in animal models,²¹ but it is difficult to generalize these results to humans, and no study has conclusively linked fertility problems to past episodes of torsion (assuming both testicles remain intact).

REFERENCES

1. Fitzpatrick JM, Desgrandchamps F, Adjali K, et al, Reten-World Study Group. Management of acute urinary retention: a worldwide survey of 6074 men with benign prostatic hyperplasia. *BJU Int* 2012;109(1):88–95.
2. Bacsu C, Van Zyl S, Rourke KF. A prospective analysis of consultation for difficult urinary catheter insertion at tertiary care centres in Northern Alberta. *Can Urol Assoc J* 2013;7(9–10):343–7.
3. Sorensen MD, Krieger JN, Rivara FP, et al. Fournier's gangrene: management and mortality predictors in a population based study. *J Urol* 2009;182(6):2742–7.

4. Goldstein I. Medical and surgical management of clitoral priapism. *J Sex Med* 2014;11(12):2838–41.
5. Dubin J, Davis JE. Penile emergencies. *Emerg Med Clin North Am* 2011;29(3):485–99.
6. Matheeußen V, Maudens KE, Anseeuw K, et al. A non-fatal self-poisoning attempt with sildenafil. *J Anal Toxicol* 2015;39(7):572–6.
7. Levey HR, Segal RL, Bivalacqua TJ. Management of priapism: an update for clinicians. *Ther Adv Urol* 2014;6(6):230–44.
8. Chen W, Sun SB, Sun LA, et al. Modified technique in treating recurrent priapism: a technique report. *Asian J Androl* 2015;17(2):329–31.
9. Soucie JM, Thun MJ, Coates RJ, et al. Demographic and geographic variability of kidney stones in the United States. *Kidney Int* 1994;46(3):893–9.
10. Hiatt RA, Friedman GD. The frequency of kidney and urinary tract diseases in a defined population. *Kidney Int* 1982;22(1):63–8.
11. Pickard R, Starr K, MacLennan G, et al. Use of drug therapy in the management of symptomatic ureteric stones in hospitalised adults: a multicentre, placebo-controlled, randomised controlled trial and cost-effectiveness analysis of a calcium channel blocker (nifedipine) and an alpha-blocker (tamsulosin) (the SUSPEND trial). *Health Technol Assess* 2015;19(63):1–172.
12. Gulati A, Prakash M, Bhatia A, et al. Spontaneous rupture of renal pelvis. *Am J Emerg Med* 2013;31(4):762.e1–3.
13. Barkin J, Rosenberg MT, Miner M. A guide to the management of urologic dilemmas for the primary care physician (PCP). *Can J Urol* 2014;21(Suppl 2):55–63.
14. Hayashi Y, Kojima Y, Mizuno K, et al. Prepuce: phimosis, paraphimosis, and circumcision. *Sci. World J* 2011;11:289–301.
15. Pohlman GD, Phillips JM, Wilcox DT. Simple method of paraphimosis reduction revisited: point of technique and review of the literature. *J Pediatr Urol* 2013;9(1):104–7.
16. Korkes F, Cabral PR, Alves CD, et al. Testicular torsion and weather conditions: analysis of 21,289 cases in Brazil. *Int Braz J Urol* 2012;38(2):222–8 [discussion: 228–9].
17. Sharp VJ, Kieran K, Arlen AM. Testicular torsion: diagnosis, evaluation, and management. *Am Fam Physician* 2013;88(12):835–40.
18. Callewaert PR, Van Kerrebroeck P. New insights into perinatal testicular torsion. *Eur J Pediatr* 2010;169(6):705–12.
19. Avery LL, Scheinfeld MH. Imaging of penile and scrotal emergencies. *Radiographics* 2013;33(3):721–40.
20. Sessions AE, Rabinowitz R, Hulbert WC, et al. Testicular torsion: direction, degree, duration and disinformation. *J Urol* 2003;169(2):663–5.
21. Turner TT, Bang HJ, Lysiak JL. The molecular pathology of experimental testicular torsion suggests adjunct therapy to surgical repair. *J Urol* 2004;172(6 Pt 2):2574–8.