

70,000 people are affected worldwide. Approximately 7% of patients with CF remain undiagnosed until adulthood ( $\geq 18$  years of age).

Because of late diagnosis and treatment advances, CF is no longer considered a pediatric disease. By 2012, adults made up nearly 50% of the population with CF, and it is expected that adult patients with CF will very soon outnumber pediatric patients. The mean predicted survival age has increased over the last decade by almost 10 years, to 41.1 years of age as of 2012.

### Diagnosis

Diagnosis of CF in adults may be obscured by an atypical and/or delayed presentation. However, the presence of certain conditions in an adult should increase suspicion for CF (Table 19).

Diagnosis is based on a combination of CF-compatible clinical findings in conjunction with either biochemical (sweat testing, nasal potential difference) or genetic (*CFTR* mutations) techniques. Use of the sweat test has been the mainstay of laboratory confirmation, although infection with *Burkholderia cepacia* is pathognomonic for CF. Once a CF diagnosis is confirmed, all patients should undergo *CFTR* mutational analysis to determine if *CFTR* modulator therapy may be an option.

Associated comorbidities in adults with CF include diabetes mellitus (present in up to 30% of patients), infertility due to azoospermia (present in 95% of men) and multifactorial causes in women, osteoporosis (present in 23% of patients), and liver disease. Liver disease occurs in 10% of patients with CF. The most common abnormality is fatty infiltration and intrahepatic cholestasis, with up to 5% to 15% of patients developing multilobular cirrhosis and portal hypertension.

### Treatment

The pillars of CF management are airway clearance, antibiotic therapy, nutritional support, and psychosocial support. The primary objectives of CF treatment are maintaining lung health and controlling/minimizing the impact of CF-affected organ disease.

The vast majority (95%) of patients with CF die from complications of lung infection. The cardinal feature of CF lung disease is pulmonary exacerbation, which serves as a significant predictor of lung function decline, decreased quality of

life, and increased morbidity. The Cystic Fibrosis Foundation (CFF) practice guidelines recommend use of chronic medications to improve lung function and reduce exacerbations. These medications include mucolytics, hydrating agents, inhaled antibiotics, oral macrolide antibiotics, and *CFTR* potentiators. Despite monitoring and management, patients may still experience exacerbations. Treatment for end-stage lung disease is with transplantation.

The goals of antibiotic treatment of CF bacterial infection(s) are to reduce bacterial burden, attempt/achieve early bacterial eradication, and/or prevent bacterial colonization of the lung (such as with *P. aeruginosa*). The CFF practice guidelines recommend that antibiotic treatment be provided for a minimum of 10 days, but a 14- to 21-day course is often necessary. Therapy may be extended even longer in patients with severe disease.

Similarly, additional recommendations are provided by the CFF for managing other CF-affected organ disease (pancreatic insufficiency; need for transplantation; sinus, liver, and bone disease; reproductive issues); these can be found on the CFF website ([www.cff.org](http://www.cff.org)).

### KEY POINTS

- The diagnosis of cystic fibrosis is based on a combination of compatible clinical findings in conjunction with either biochemical (sweat testing, nasal potential difference) or genetic (*CFTR* mutations) techniques.
- The pillars of cystic fibrosis management are airway clearance, antibiotic therapy, nutritional support, and psychosocial support.

## Diffuse Parenchymal Lung Disease

### Overview

Interstitial lung diseases were initially named because of abnormalities identified in the pulmonary interstitium on histopathology. However, these disorders also typically involve the distal lung parenchyma, smaller airways, vasculature, and pleura. As a result, diffuse parenchymal lung disease (DPLD) is a more accurate and inclusive term for describing these diseases than is interstitial lung disease. DPLD represents a heterogeneous group of disorders that are classified based on similar clinical, radiographic, physiologic, and pathologic criteria. The term DPLD excludes pulmonary hypertension and COPD. In general, DPLDs are not infectious in origin, they most commonly present with dyspnea and cough, and imaging abnormalities are most often diffuse rather than focal.

### Classification and Epidemiology

In comparison with the prevalence of either COPD or cardiogenic causes of shortness of breath, the DPLDs are extremely

**TABLE 19. Conditions Suggesting the Possible Diagnosis of Cystic Fibrosis in Adults**

Recurrent pancreatitis
Male infertility
Chronic sinusitis
Severe nasal polyposis
Nontuberculous mycobacterial infection
Allergic bronchopulmonary aspergillosis
Bronchiectasis
Positive sputum culture for <i>Burkholderia cepacia</i>

## Diffuse Parenchymal Lung Disease

rare. Accurate estimates of the prevalence of DPLD remain elusive. Current estimates place the prevalence of DPLD at approximately 70 per 100,000 persons. Although this is the most widely accepted prevalence, it likely underestimates the true prevalence of the disorder. Approximately 30% to 40% of cases are idiopathic.

There are hundreds of DPLDs, which often leads to confusion on how best to diagnose them. The most useful classification system defines those with a known cause or association versus those that are idiopathic (Table 20). Pulmonary pathology specimens are the gold standard for diagnosis of DPLD of both unknown and known causes; however, for the idiopathic

**TABLE 20. Classification and Distinguishing Features of Select Forms of Diffuse Parenchymal Lung Disease**

<b>Known Causes</b>	
Drug induced	Examples: amiodarone, methotrexate, nitrofurantoin, chemotherapeutic agents (see www.pneumotox.com for a complete listing)
Smoking related	"Smokers" respiratory bronchiolitis characterized by gradual onset of persistent cough and dyspnea. Radiograph shows ground-glass opacities and thickened interstitium. Smoking cessation improves prognosis.  Desquamative interstitial pneumonitis and pulmonary Langerhans cell histiocytosis are other histopathologic patterns associated with smoking and DPLD.
Radiation	May occur 6 weeks to months following radiation therapy
Chronic aspiration	Aspiration is often subclinical and may exacerbate other forms of DPLD
Pneumoconioses	Asbestosis, silicosis, berylliosis
Connective tissue diseases	
Rheumatoid arthritis	May affect the pleura (pleuritis and pleural effusion), parenchyma, airways (bronchitis, bronchiectasis), and vasculature. The parenchymal disease can range from nodules to organizing pneumonia to usual interstitial pneumonitis.
Systemic sclerosis	Nonspecific interstitial pneumonia pathology is most common; may be exacerbated by aspiration due to esophageal involvement; antibody to Scl-70 or pulmonary hypertension portends a poor prognosis. Monitoring of diffusing capacity for early involvement is warranted.
Polymyositis/ dermatomyositis	Many different types of histology; poor prognosis.
Other connective tissue diseases	Varying degrees of lung involvement and pathology can be seen in other forms of connective tissue disease.
Hypersensitivity pneumonitis	Immune reaction to an inhaled low-molecular-weight antigen; may be acute, subacute, or chronic. Noncaseating granulomas are seen.
<b>Unknown Causes</b>	
Idiopathic interstitial pneumonias	
Idiopathic pulmonary fibrosis	Chronic, insidious onset of cough and dyspnea, usually in a patient aged >50 y. Usual interstitial pneumonia pathology (honeycombing, bibasilar infiltrates with fibrosis). Diagnosis of exclusion.
Acute interstitial pneumonia	Dense bilateral acute lung injury similar to acute respiratory distress syndrome; 50% mortality rate.
Cryptogenic organizing pneumonia	May be preceded by flu-like illness. Radiograph shows focal areas of consolidation that may migrate from one location to another.
Sarcoidosis	Variable clinical presentation, ranging from asymptomatic to multiorgan involvement. Stage 1: hilar lymphadenopathy. Stage 2: hilar lymphadenopathy plus interstitial lung disease. Stage 3: interstitial lung disease. Stage 4: fibrosis. Noncaseating granulomas are hallmarks.
<b>Rare DPLD with Well-Defined Features</b>	
Lymphangioleiomyomatosis	Affects women in their 30s and 40s. Associated with spontaneous pneumothorax and chylous effusions. Chest CT shows cystic disease.
Chronic eosinophilic pneumonia	Chest radiograph shows "radiographic negative" heart failure, with peripheral alveolar infiltrates predominating. Other findings may include peripheral blood eosinophilia and eosinophilia on bronchoalveolar lavage.
Pulmonary alveolar proteinosis	Median age of 39 years, and males predominate among smokers but not in nonsmokers. Diagnosed via bronchoalveolar lavage, which shows abundant protein in the airspaces. Chest CT shows "crazy paving" pattern.
DPLD = diffuse parenchymal lung disease.	

forms of disease, histopathologic patterns correlate with disease prognosis as well as response to anti-inflammatory treatment (such as glucocorticoids).

## Diagnostic Approach and Evaluation

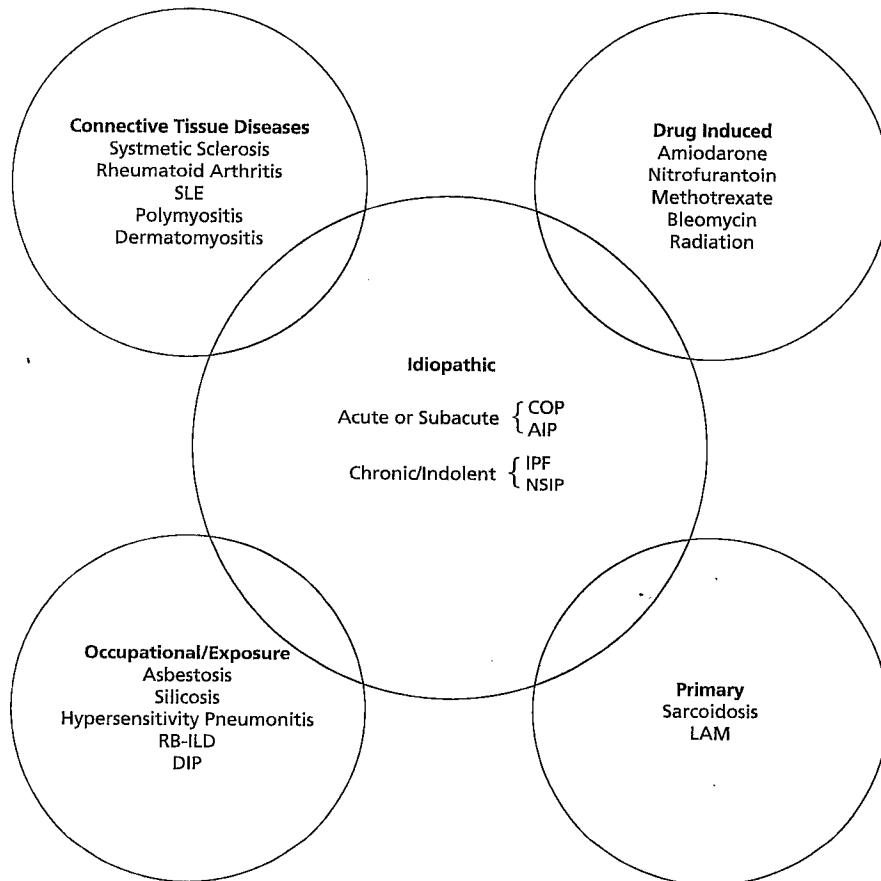
Patients with DPLD most often present with nonspecific symptoms of dyspnea and cough. A careful history with attention to time course is useful in raising the suspicion for DPLD and narrowing the differential diagnosis. For symptoms of shorter duration, lasting days to weeks rather than over months, infection and heart failure remain the most likely cause. If these causes are excluded or empiric treatment in this population is unsuccessful, the acute- or subacute-onset DPLDs should be considered.

Causes of DPLD can be classified into several broad categories, which include connective tissue diseases, occupational or other exposures, drug-induced lung injuries, idiopathic disorders, and primary disorders (Figure 7). For each of these categories, the differential diagnoses overlap with the idiopathic interstitial pneumonias. Therefore, in patients with suspected DPLD, a careful history that includes the time

course of symptoms, smoking and exposure history, rheumatologic review of systems, family history of autoimmune and lung disease, and past medication use helps assess potential risk and focus the differential diagnosis.

Plain chest radiography findings may be highly variable in patients with DPLD. Chest films may show increased interstitial reticular or nodular infiltrates in different patterns of distribution, but they may be normal in up to 20% of patients. Therefore, if clinical suspicion for DPLD exists, the evaluation should not stop if the chest radiograph is normal.

Characteristics on high-resolution CT (HRCT) of the chest have pulmonary pathology correlates that can help narrow the differential diagnosis. HRCT provides detailed resolution of the pulmonary parenchymal architecture. Advances in HRCT imaging techniques along with improved understanding of the correlation between HRCT findings and surgical biopsy histopathology findings have made HRCT the diagnostic tool of choice for evaluation of DPLD. There is little role for the use of conventional CT imaging (5-mm slice thickness) for this population given the limits of its resolution. HRCT, clinical presentation (including time course of symptoms), physical findings, and, when necessary, lung biopsy and histopathology allow clinicians to reach selected diagnoses from hundreds of DPLDs.



**FIGURE 7.** Broad categories of diffuse parenchymal lung disease. AIP = acute interstitial pneumonia; COP = cryptogenic organizing pneumonia; DIP = desquamative interstitial pneumonia; IPF = idiopathic pulmonary fibrosis; LAM = lymphangioleiomyomatosis; NSIP = nonspecific interstitial pneumonia; RB-ILD = respiratory bronchiolitis-associated interstitial lung disease; SLE = systemic lupus erythematosus.

For patients with more chronic symptoms, pulmonary function testing is helpful diagnostically to exclude obstructive lung disease as a primary cause of a patient's dyspnea symptoms. When restrictive or combined obstructive/restrictive diseases are identified and the presentation is more insidious (>6 months), DPLD should be considered.

Once there is clinical suspicion of DPLD, pulmonary consultation is appropriate.

**KEY POINTS**

- Causes of diffuse parenchymal lung disease can be classified into several broad categories, which include connective tissue diseases, occupational or other exposures, drug-induced lung injuries, idiopathic disorders, and primary disorders.
- The diagnosis of diffuse parenchymal lung disease should be considered in patients with insidious onset dyspnea and cough (>6 months) once infection, heart failure, and COPD are ruled out; consistent pulmonary function testing has a restrictive or combined obstructive/restrictive pattern.
- HVC** ◦ High-resolution CT is the diagnostic tool of choice for evaluation of diffuse parenchymal lung disease; there is little role for plain chest radiography or conventional CT imaging (5-mm slice thickness) given the limits of their resolution.

**High-Resolution CT Scanning**

**Patterns and Distribution**

Disease patterns on HRCT generally correlate with pathologic findings on open lung biopsy. Specific terminology is used to describe findings noted on HRCT (Table 21). This terminology, in conjunction with the distribution of disease, allows the thoracic radiologist to describe patterns of disease associated with specific pathology (Table 22). Coexisting patterns of disease are common and can make definitive characterization from the CT scan imaging alone difficult. The combination of history, physical examination, serologic evaluation, and HRCT can obviate the need for diagnostic lung biopsy in 60% or more of patients. For those without a clear diagnosis following this evaluation, surgical lung biopsy may be considered. [2]

**Associated Findings**

Outside of the lung parenchyma, additional findings may be present in the mediastinum, pleura, and soft tissues that assist in making a diagnosis. For example, mediastinal and hilar lymphadenopathy is a common finding in sarcoidosis, whereas significantly enlarged lymph nodes are a rare finding in patients with idiopathic pulmonary fibrosis (IPF). Similarly, pleural effusions are rare in IPF but can be seen in connective tissue disease-associated DPLD such as systemic lupus erythematosus. Pleural plaques can help identify a history of asbestos

**TABLE 21. Thoracic Radiology Terminology for Parenchymal Findings in DPLD**

Pattern	Characteristics	Pathophysiology
Septal	Peripheral: short lines that extend to the pleura Central: polygonal arcades that outline the secondary pulmonary lobule	Disease affecting any component of the septum (connective tissue containing lymphatics and pulmonary venules)
Reticular	On radiograph: interlacing lines that suggest a net	HRCT further defines the abnormality, whether septal lines or walls of a cyst
Nodular	Spherical lesions (<1 cm) with widespread distribution Locations: centrilobular, lymphatic (septal), or random	Centrilobular: artery and small airway pathology Septal (see above)
Reticulonodular	On radiograph: intersection of innumerable lines producing the effect of micronodules HRCT: Discerns the location of nodules as either septal or centrilobular	As above
Ground glass	Hazy increased opacity with preservation of bronchial and vascular markings	Partial filling of airspaces; interstitial thickening from fluid, cells, and/or fibrosis; partial collapse of alveoli; increased capillary blood volume or a combination of these
Consolidation	Denser opacity that obscures vascular markings, unlike ground-glass opacity Air bronchograms may be present	Exudate or other product that replaces alveolar air
Honeycomb change	Closely approximated ring shadows that resemble a honeycomb; typically subpleural with well-defined walls	Destroyed and fibrotic lung containing cystic airspaces
Mosaic attenuation	Patchy regions of differing attenuation	On expiratory images, decreased areas of attenuation represent bronchial or bronchiolar obstruction

DPLD = diffuse parenchymal lung disease; HRCT = high-resolution CT.


TABLE 22. Patterns of Disease Associated with Diagnosis of DPLD

Lung Disease	Imaging	Comments
Acute interstitial pneumonia	Diffuse ground-glass with consolidation	Indistinguishable from ARDS with a risk factor
Organizing pneumonia	Patchy ground glass, consolidation, peripheral and basal predominance	Connective tissue diseases, infections, vasculitis, lymphoma, adenocarcinoma
Idiopathic pulmonary fibrosis/usual interstitial pneumonia	Basal- and peripheral-predominant septal line thickening with traction bronchiectasis and honeycomb changes	This is the usual interstitial pneumonia pattern and can be seen in connective tissue disease, asbestosis, and chronic hypersensitivity pneumonitis; idiopathic pulmonary fibrosis is a diagnosis of exclusion
Nonspecific interstitial pneumonia	Ground glass, basal predominance	Idiopathic and common finding in connective tissue disease
Respiratory bronchiolitis	Centrilobular nodules and ground-glass opacity in an upper-lung predominant distribution	May be an asymptomatic finding in an active smoker
Desquamative interstitial pneumonia	Basal- and peripheral-predominant ground-glass opacity with occasional cysts	—
Hypersensitivity pneumonitis	Acute: centrilobular micronodules that are upper- and mid-lung predominant  Chronic: mid- and upper-lung predominant septal lung thickening with traction bronchiectasis; usual interstitial pneumonia pattern may be seen	Acute: associated with flulike illness  Chronic: often cannot identify a causative antigen
Sarcoidosis	Upper-lobe predominant fibrosis; mediastinal and hilar lymphadenopathy; cystic changes including development of aspergilloma; airways-centered changes	Findings for sarcoidosis are often not specific; DPLD with diffuse mediastinal and hilar lymphadenopathy greater than 2 cm in size should raise suspicion

ARDS = acute respiratory distress syndrome; DPLD = diffuse parenchymal lung disease.

exposure and possible asbestosis. Bone abnormalities are notable in individuals with ankylosing spondylitis.

### Surgical Lung Biopsy

Video-assisted thoracoscopic lung biopsy is an option for patients who have disparate findings on history, physical examination, imaging, and laboratory studies. Although generally well tolerated, there are reports of individuals whose disease has worsened after the procedure. Therefore, risk stratification and assessment of potential benefit are necessary when deciding whether to pursue biopsy. 

## Diffuse Parenchymal Lung Diseases with a Known Cause

### Smoking-Related Diffuse Parenchymal Lung Disease

Tobacco smoke is associated with the development of multiple DPLDs, including IPF. There are also several disorders that generally only develop in individuals who have an active smoking history.

Respiratory bronchiolitis-associated interstitial lung disease is used to describe disease in active smokers who have imaging findings of centrilobular micronodules with a pathologic finding of respiratory bronchiolitis on biopsy.

Desquamative interstitial pneumonia is due to extensive, diffuse macrophage filling of alveolar spaces with predominant cough and dyspnea symptoms and bilateral ground-glass opacities on chest imaging. Pulmonary Langerhans cell histiocytosis is characterized by thin-walled cysts with accompanying nodules and is often associated with pulmonary hypertension. All of these diseases are subacute and present in active smokers. Pulmonary function tests usually reveal an obstructive pattern with a severely decreased DLCO in individuals with more severe disease. For those with milder disease, pulmonary function tests can be normal, restrictive, or obstructive. Cessation of smoking is the primary management. Although glucocorticoids are used in individuals with more severe disease, the benefit of their use is uncertain.

#### KEY POINTS

- Tobacco smoke is associated with the development of multiple diffuse parenchymal lung diseases, including idiopathic pulmonary fibrosis.
- Cessation of smoking is the primary management for smoking-related diffuse parenchymal lung disease.

HVC

### Connective Tissue Diseases

The prevalence of pulmonary manifestations in individuals with known connective tissue diseases is extremely high.

Patients with DPLD associated with connective tissue disease typically present with dyspnea.

DPLD is most often identified after an established diagnosis of connective tissue disease, although occasionally DPLD will be the first manifestation of connective tissue disease. As a result, all patients with suspected DPLD should be screened with a careful rheumatologic review of systems and physical examination to assess for the possibility of connective tissue disease. It is important to identify an underlying autoimmune disorder because of its effect on prognosis, drug therapy recommendations, and management of comorbidities that may adversely affect pulmonary outcomes.

For example, progressive pulmonary disease is now the primary cause of mortality in systemic sclerosis. Cyclophosphamide may have some short-term benefit in treating the lung disease, and managing the gastroesophageal dysmotility associated with systemic sclerosis may help avoid aspiration and further lung injury.

Another connective tissue disease commonly associated with DPLD is rheumatoid arthritis. DPLD associated with rheumatoid arthritis is more common in males than females and, as with other autoimmune diseases, may present prior to manifestations of arthritis. Parenchymal lung disease may include pleural disease, rheumatoid nodules, bronchitis, bronchiectasis, organizing pneumonia, and bronchiolitis, as well as a pattern of usual interstitial pneumonia (UIP). Similar to individuals with IPF, a UIP pattern on CT imaging indicates a poor prognosis. Currently, these manifestations of rheumatoid arthritis are often treated with glucocorticoids and disease-modifying agents; however, there are little data to suggest clear efficacy for this strategy.

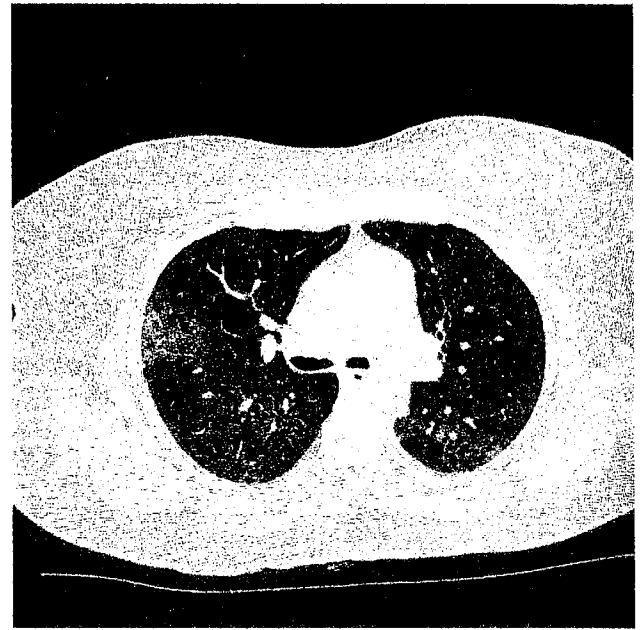
### KEY POINTS

- The prevalence of pulmonary manifestations in individuals with known connective tissue diseases is extremely high, and these patients typically present with dyspnea.
- All patients with diffuse parenchymal lung disease should be clinically assessed for an underlying autoimmune disorder because of its effect on prognosis, drug therapy recommendations, and management of comorbidities.

### Hypersensitivity Pneumonitis

Hypersensitivity pneumonitis (HP) is the result of an immunologic response to repetitive inhalation of antigens. The most common sources of antigens are thermophilic actinomyces, fungi, and bird droppings. Antigens, however, are not limited to these origins and can include bacterial, protozoal, animal, or insect proteins, and even small molecular chemical compounds.


The acute form of HP presents within 48 hours of a high-level exposure and will often be associated with fevers, flu-like symptoms, cough, and shortness of breath. Radiographic imaging can demonstrate bilateral hazy opacities, while HRCT imaging of the chest shows findings of ground-glass opacities and centrilobular micronodules that are upper- and mid-lung predominant (Figure 8). Symptoms typically wane within 24



**FIGURE 8.** Chest CT demonstrating hypersensitivity pneumonitis with patchy, bilateral ground-glass opacities and centrilobular micronodules in this mid-lung section.

to 48 hours after removal from the exposure. Recurrence of symptoms with exposure to the respiratory antigen is the hallmark of this disorder, and careful attention to the history will help identify the cause.

Subacute and chronic forms of the disease also occur and are believed to be associated with more chronic low-level exposures to inhaled antigen. Bird fancier's disease is the classic example of this disorder, in which individuals are chronically exposed to an antigen from a domestic bird within the home. Patients will ultimately present with cough, dyspnea, malaise, and weight loss. HRCT findings include centrilobular micronodules in upper- and mid-lung distribution as well as evidence of septal line thickening and fibrosis.

The primary treatment is to remove the offending antigen. For this reason, it is extremely important to obtain a careful history to identify potential exposures. Glucocorticoids are used for patients with more severe symptoms and for those with evidence of fibrosis. 

### KEY POINTS

- The most common sources of antigens causing hypersensitivity pneumonitis are thermophilic actinomyces, fungi, and bird droppings; symptoms wane 24 to 48 hours after removal from exposure and recur with re-exposure to respiratory antigens.
- Radiographic imaging in hypersensitivity pneumonitis may demonstrate bilateral hazy opacities, while high-resolution CT imaging of the chest shows findings of ground-glass opacities and centrilobar micronodules that are upper- and mid-lung predominant.

(Continued)

**KEY POINTS (continued)**

- The primary treatment for hypersensitivity pneumonitis is to remove the offending antigen; glucocorticoids are used for patients with more severe symptoms and for those with evidence of fibrosis.

**Drug-Induced Parenchymal Lung Disease**

In patients who present with diffuse abnormalities on chest imaging, drug-induced parenchymal lung disease should be considered and investigated. Hundreds of drugs have been described in association with drug-induced lung disease. A few classic drug-induced lung syndromes are described in Table 23. Symptoms can develop acutely

after drug initiation, but some medications have more subacute symptoms. Therefore, a careful medication history should be taken and should include medications that may have been discontinued after chronic treatment. The primary management of these disorders is removal of the offending agent.

**Radiation-Induced Parenchymal Lung Disease**

Symptoms of acute radiation pneumonitis typically occur 6 to 12 weeks after exposure. Patients present with cough, dyspnea, and occasionally fever and malaise. Differentiating these symptoms from infection and drug-induced pneumonitis is difficult given the common use of chemotherapy in combination with radiation. HRCT shows hazy ground-glass opacities.


**TABLE 23. Select Drug-Induced Parenchymal Lung Diseases**

Drug	Clinical Points	Radiographic Findings and Treatment
Amiodarone	More common in: Older patients Increased dosage and higher cumulative dose First year of therapy (but can occur late)	Multiple radiographic presentations possible including ground-glass opacities, subpleural nodules, and reticular abnormalities  Very long half-life prevents clearance from the pulmonary parenchyma: Rare improvement with discontinuation of the drug alone High risk of recurrence with tapering of glucocorticoids
Methotrexate	Occurs in less than 5% of patients treated Unpredictable time to presentation No clear correlation between dose and disease severity	Diffuse reticular and ground-glass attenuation Patients generally do well after stopping medication Glucocorticoids are often given and duration is based on response
Nitrofurantoin	Acute (more common): Fever, chills, cough, shortness of breath, chest pain; rash can occur in 10%-20% of patients Peripheral eosinophils common  Chronic: Distinct from the acute form Onset months to years after prolonged exposure	Acute: Faint bilateral lower lobe septal lines; moderate pleural effusions may be present. Treatment: Often will resolve with discontinuation but will recur with repeat exposure.  Chronic: Reticular opacities with subpleural lines and thickened peri-bronchovascular areas. Treatment: Possible benefit of glucocorticoids from anecdotal reports.
Busulfan	Occurs in less than 8% of patients treated Used solely as a conditioning regimen for HSCT today; often combined with other agents associated with pulmonary toxicity Injury typically occurs 30 days to 1 year after exposure	Multiple patterns including: ground glass opacities, reticulation, bibasilar septal lines, asymmetric peripheral and peribronchial consolidation, centrilobar nodules, and dependent consolidation  Optimal treatment unknown and is often supportive Glucocorticoids may be used for more progressive disease
Bleomycin	Risk significantly increases with cumulative dose Increased age, renal insufficiency, concomitant chemotherapy and/or radiation also increases risk of toxicity  Typically subacute presentation 1 to 6 months after exposure; may resemble hypersensitivity pneumonitis but with more rapid onset and progressive course	Imaging patterns suggest the multiple possible pathologic findings seen:  Consolidation with ground glass (diffuse alveolar damage) Septal line thickening, traction bronchiectasis, and honey comb change (end-stage fibrosis)  Patchy ground glass with subpleural consolidation or peribronchial consolidation (organizing pneumonia) Diffuse ground glass with centrilobar micronodules (hypersensitivity pneumonitis)  Glucocorticoids are used for more severe disease and disease may recur with tapering of steroids

HSCT = hematopoietic stem cell transplantation.



The factor that is most pathognomonic of radiation pneumonitis is the imaging finding of a nonanatomic straight line demarcating involved versus uninvolved lung parenchyma. Although abnormalities most often occur within the radiation field, it is possible for changes to occur outside of the field as well. Typically, acute changes will resolve within 6 months, but some patients may be left with a well-demarcated area of fibrosis, volume loss, and bronchiectasis.

Treatment of radiation pneumonitis is determined by the severity of symptoms. For patients with evidence of organizing pneumonia, there is likely a benefit to the use of glucocorticoids. Glucocorticoid therapy use is based on animal data suggesting a beneficial effect by suppressing the inflammatory response from acute radiation. For those with milder disease, the inflammation may resolve, obviating the need for glucocorticoids. 

### KEY POINTS

- In patients who present with diffuse abnormalities on chest imaging, drug-induced lung disease should be considered and investigated.
- Radiation pneumonitis presents with cough, dyspnea, and hazy ground-glass opacities (pathognomonic finding is a nonanatomic straight line between involved and uninvolved lung) on high-resolution CT 6 to 12 weeks after radiation exposure.

## Diffuse Parenchymal Lung Diseases with an Unknown Cause



### Idiopathic Pulmonary Fibrosis

IPF is the most common idiopathic interstitial pneumonia. It occurs predominantly in older individuals; the diagnosis of IPF is rare in those younger than 60 years of age. Gradual onset of dyspnea and cough over months to years is typical. Physical examination reveals dry inspiratory crackles at the bases. Nearly 50% of patients will have clubbing. More severe disease is associated with secondary pulmonary hypertension and evidence of right-sided heart failure on examination. Initial evaluation findings are often similar to more common conditions such as heart failure (due to crackles on lung examination) or COPD (a smoking history is common). Pulmonary function testing will most often show a restrictive abnormality with a reduced diffusing capacity; however, an isolated reduction in diffusing capacity and normal pulmonary function can also be seen (see Pulmonary Diagnostic Tests). All other identifiable causes of fibrotic lung disease must be excluded before the diagnosis can be made. When select HRCT features are present that establish a definite pattern of UIP (see Table 22) in the appropriate clinical setting, the diagnosis of IPF is established.

Prognosis remains poor, and individuals diagnosed with IPF have an estimated average survival of 3 to 5 years. There is, however, variability in the disease course. Some individuals


will have slowly progressive declines in their forced vital capacity, while others can have a rapid decline leading to death. Still others will demonstrate stepwise declines in their pulmonary function tests with acute declines followed by subsequent stabilization.

An acute decline may manifest as an acute exacerbation of IPF. This is a well defined clinical syndrome that develops in a small portion of patients with IPF. The clinical course of an acute exacerbation is acute to subacute onset (typically <30 days) of worsening dyspnea, and the medical evaluation does not reveal another cause for dyspnea such as infection, heart failure, or pulmonary embolism. HRCT shows new-onset diffuse ground-glass opacities. Patients may develop frank respiratory failure due to an exacerbation or stabilize at a new, worsened baseline.

The most common cause of death in IPF is respiratory failure. For individuals who develop severe respiratory distress for which there is no underlying reversible cause, supportive mechanical ventilation is of little long-term benefit. Therefore, the most recent evidence-based consensus statement recommends against mechanical ventilation for individuals with acute respiratory failure due to either progression or an acute exacerbation of IPF. In these circumstances, the focus should be on palliation of the patient's underlying dyspnea.

Treatment of IPF is primarily supportive, with optimization of fitness and oxygenation, as well as treatment of associated conditions. Recent clinical trials have led to a clearer understanding of the pharmacologic approach to patients with carefully diagnosed IPF. Therapies used in the past focused on anti-inflammatory therapy (for example, prednisone), with or without immune modulators (such as azathioprine). These therapies should be avoided because they were associated with increased mortality when compared with placebo in patients with mild to moderate respiratory impairment due to IPF. Antioxidant therapy with *N*-acetylcysteine was not found to be beneficial in decreasing the progression of IPF or reducing the frequency of exacerbations of IPF.

The most current models of disease focus on the interplay among alveolar epithelial cells, the extracellular matrix, and myofibroblasts that lead to fibrosis. Knowledge of these pathways has led to the development of two newly approved FDA therapies for the treatment of IPF: nintedanib and pirfenidone. Nintedanib is a tyrosine kinase inhibitor known to block pathways that lead to activation of the fibroblast. Similarly, pirfenidone is a novel therapeutic agent that regulates transforming growth factor  $\beta$  (TGF- $\beta$ ) and tumor necrosis factor  $\alpha$  (TNF- $\alpha$ ) activity through an unknown mechanism. Although these therapies are an important step forward in the management of IPF, they are not curative.

Lung transplantation remains the only therapy that clearly prolongs life in a select subset of patients with IPF. Early referral to a lung transplant center for suitable individuals interested in transplantation remains an appropriate early intervention for individuals with IPF. 



**KEY POINTS**

- Treatment of idiopathic pulmonary fibrosis is supportive, with optimization of fitness and oxygenation, as well as treatment of associated conditions; lung transplantation may be appropriate in a select subset of patients.
- HVC**
- The most recent evidence-based consensus statement recommends against mechanical ventilation for individuals with acute respiratory failure due to either progression or an acute exacerbation of idiopathic pulmonary fibrosis.

**Nonspecific Interstitial Pneumonia**

Similar to IPF, NSIP is a disease that predominantly affects the lower lobes of the lung. Unlike IPF, NSIP tends to affect a younger patient population and is strongly associated with connective tissue disease. The largest group of patients with NSIP is those with systemic sclerosis; however, many autoimmune disorders have been associated with NSIP, including rheumatoid arthritis, systemic lupus erythematosus, polymyositis/dermatomyositis, and undifferentiated connective tissue disease. Some patients may initially present with only pulmonary manifestations of their underlying autoimmune disorder. For these individuals, the initial diagnosis may be idiopathic NSIP. This cohort of patients should receive continued surveillance for development of connective tissue disease. A careful review of systems is a key component of patient follow-up; new-onset symptoms should prompt further diagnostic assessments. A definitive diagnosis may help to better define the prognosis. The basis for immunosuppressive/immune-modulatory medications in patients with NSIP stems from the treatment response observed in the Scleroderma Lung Study, which was specific for patients with scleroderma and the inflammatory form of NSIP. The generalizability of these data in patients with NSIP due to other causes is less understood. In general, the prognosis for patients with an underlying autoimmune disorder is better than those with IPF; however, more severely affected pulmonary function and more extensive disease on CT imaging portend a worse prognosis.

**KEY POINT**

- Nonspecific interstitial pneumonia predominantly affects the lower lobes of the lung, tends to affect a younger patient population, and is strongly associated with connective tissue disease (most often systemic sclerosis).

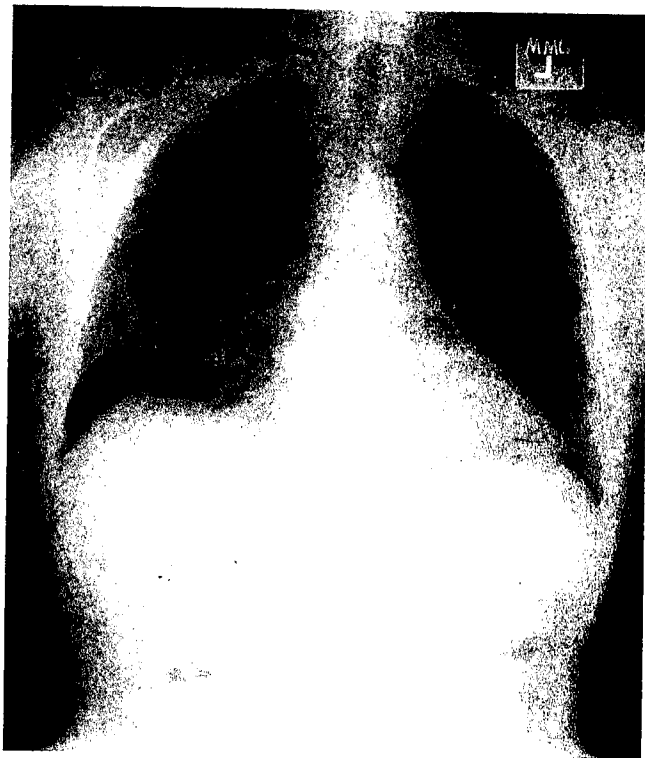
**Cryptogenic Organizing Pneumonia**

Organizing pneumonia is a patchy process that involves proliferation of granulation tissue within alveolar ducts, alveolar spaces, and surrounding areas of chronic inflammation. There are many known causes of this pattern, including acute infections and autoimmune disorders like rheumatoid arthritis. The term cryptogenic organizing pneumonia (COP) is reserved

for individuals who have this pattern but do not have a clear associated cause.

Patients with COP will typically present with symptoms over 6 to 8 weeks that mimic community-acquired pneumonia. The vast majority of individuals will present with symptoms of less than 3 months' duration. Patients typically present with bilateral diffuse alveolar opacities on chest radiograph with normal lung volumes (**Figure 9**). Patients may also present with multiple large nodules or masses that are predominantly peripheral. Although these findings are suggestive of an organizing pneumonia pattern, they are not specific to this disease. Typically, an initial empiric treatment for infection is given but fails; subsequently, noninfectious causes are then considered. Because the imaging findings are not specific, a bronchoscopic or surgical lung biopsy may be necessary to establish the diagnosis.

The prognosis for COP is typically favorable with a good response to glucocorticoids. Similar to idiopathic NSIP, individuals with COP should undergo examination and careful review of systems to ensure that there is not an underlying connective tissue disease. Also similar to idiopathic NSIP, individuals may develop manifestations of an underlying autoimmune disease subsequent to their initial pulmonary presentation.



**FIGURE 9.** Chest radiograph showing cryptogenic organizing pneumonia with multiple patchy bilateral alveolar opacities that are nonspecific and may be difficult to distinguish from more typical infectious pneumonia. Infiltrates may be migratory with resolution of established opacities as new areas appear on serial imaging. Imaging may also be nonspecific, showing interstitial infiltrates and alveolar opacification or showing one or more rounded nodules that may be interpreted as malignancy.



In COP, recurrence with tapering of the glucocorticoid dosage is common; however, these recurrences most often respond to readministration and tapering of glucocorticoids. For those with multiple recurrences, careful re-examination for an underlying cause (such as an autoimmune disorder or ongoing exposure) is necessary. This group of patients may require long-term immunosuppressive therapy.

**KEY POINT**

- The prognosis for cryptogenic organizing pneumonia is typically favorable with a good response to glucocorticoids.



**Acute Interstitial Pneumonia**

Acute interstitial pneumonia develops rapidly over days to weeks and results in progressive hypoxemic respiratory failure. Radiographic examination reveals bilateral alveolar opacities consistent with pulmonary edema; these findings cannot be reliably discerned from acute respiratory distress syndrome. Similarly, open lung biopsy specimens demonstrate diffuse alveolar damage. Unlike acute respiratory distress syndrome, there are no clearly associated risk factors for respiratory failure. Therefore, the history should be carefully reviewed to ensure that there is nothing to suggest aspiration, sepsis, pneumonia, or inhalational injury that might be amenable to treatment. Consensus recommendations advocate treatment with glucocorticoids. Although little evidence-based data exist, anecdotal reports suggest an improved outcome with this therapy. In addition to glucocorticoids, supportive care (with low tidal volume ventilation and careful attention to avoid complications of critical illness) remains the mainstay of therapy. Mortality rates remain extremely high (approximately 50%). Individuals who recover from the initial illness may relapse or develop chronic lung disease.

**KEY POINT**

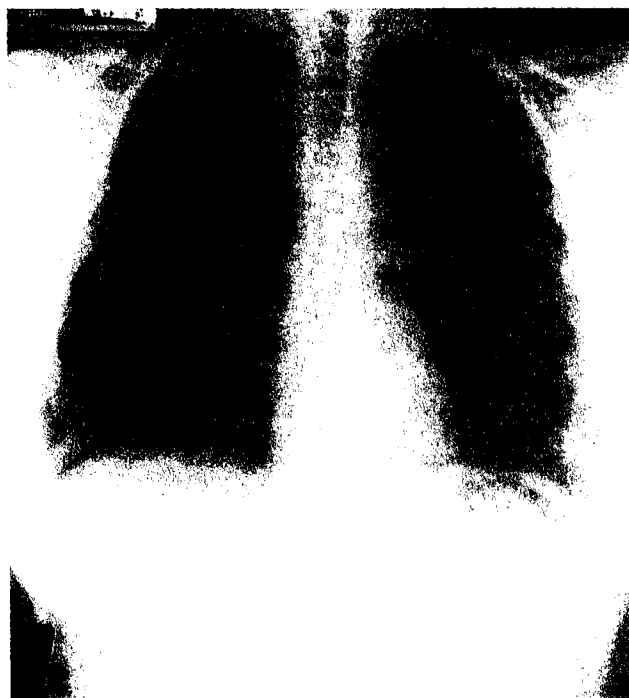
- Acute interstitial pneumonia develops rapidly over days to weeks and results in progressive hypoxemic respiratory failure; treatment consists of glucocorticoids and supportive care, but mortality is still high at 50%.



**Sarcoidosis**

Sarcoidosis is a multisystem granulomatous disease of unclear cause with a predilection for the lung; pulmonary involvement occurs in more than 90% of patients.

Many patients with pulmonary sarcoidosis are asymptomatic, and lung involvement is frequently discovered incidentally on chest imaging (Figure 10). Pulmonary sarcoidosis is classified based on the radiographic pattern (Table 24), and spontaneous regression of disease is common. For example, greater than 90% of those with stage I findings have radiographic resolution of their findings within 2 years, whereas 20% of those with stage II or III had spontaneous improvement in their imaging findings over this same time interval.



**FIGURE 10.** Chest radiograph showing stage I pulmonary sarcoidosis with hilar lymphadenopathy and normal lung parenchyma.

**TABLE 24.** Plain Radiographic Staging of Pulmonary Sarcoidosis

Stage	Radiographic Pattern	Clinical Course and Comments
0	Normal	—
I	Hilar lymphadenopathy with normal lung parenchyma	>90% will have spontaneous resolution without treatment
II	Hilar lymphadenopathy with abnormal lung parenchyma	Approximately 20% rate of spontaneous improvement without treatment
III	No lymphadenopathy with abnormal lung parenchyma	Approximately 20% rate of spontaneous improvement without treatment
IV	Parenchymal changes with fibrosis and architectural distortion	—


Pulmonary function tests will often be abnormal with obstructive, restrictive, or combined physiology on testing. Because sarcoidosis is a diagnosis of exclusion, a careful assessment is warranted in all patients to clarify the diagnosis. Although tissue biopsy (most often via bronchoscopy with transbronchial and lymph node biopsy) is usually required to diagnose sarcoidosis and exclude significant alternative diagnoses, there are several specific clinical situations in which biopsy is not considered necessary (Table 25).

**TABLE 25. Clinical Presentations of Sarcoidosis that Do Not Warrant a Biopsy**

Syndrome/Sign	Comments
Asymptomatic bilateral hilar lymphadenopathy	No evidence of fevers, malaise, or night sweats to suggest a malignancy
Löfgren syndrome	Bilateral hilar lymphadenopathy, migratory polyarthralgia, erythema nodosum, and fevers
Heerfordt syndrome	Anterior uveitis, parotiditis, fevers (uveoparotid fever), and facial nerve palsy

**CONT.** Glucocorticoids are the mainstay of therapy. Treatment is usually limited to those with evidence of clinical symptoms from organ dysfunction. Because there is a high rate of spontaneous remission and stability, most treatment protocols favor a period of observation without therapy. The decision to initiate glucocorticoid therapy for sarcoidosis should be based on symptoms or physiologic impairment that is attributable to sarcoid disease. There is a paucity of randomized controlled trials to provide guidance regarding whether glucocorticoid therapy will provide definitive benefit. Retrospective data suggest that treatment with glucocorticoids may have short-term symptomatic benefit but does not clearly affect long-term disease outcomes. If glucocorticoids are used for treatment of sarcoidosis, studies suggest that low-dose or alternate-day treatment strategies are as efficacious as higher-dose strategies and appear to have fewer side effects. Studies also show that once glucocorticoid therapy has begun, many patients will remain on this therapy for prolonged periods. Tapering regimens are often prolonged and should be based on clear, attributable symptoms or physiologic metrics in conjunction with careful and frequent follow-up.

Pulmonary hypertension may develop in some individuals with sarcoidosis owing to multiple physiologic reasons, including DPLD, pulmonary vascular disease, pulmonary artery compression from significant lymphadenopathy, left ventricular dysfunction, and pulmonary venous occlusion. For individuals who develop pulmonary hypertension without evidence of left ventricular dysfunction, mortality is significantly higher, with a median survival of approximately 3 years. For this group of patients, as well as individuals with significant limitations due to pulmonary disease, lung transplantation is a viable therapeutic option.

For a discussion of the musculoskeletal manifestations of sarcoidosis, see MKSAP 17 Rheumatology. 

**KEY POINTS**

- Pulmonary involvement occurs in more than 90% of patients with sarcoidosis, but is often asymptomatic.
- Glucocorticoids are the mainstay of therapy for symptomatic pulmonary sarcoidosis.

**Lymphangioleiomyomatosis**

Lymphangioleiomyomatosis is a rare disorder that occurs sporadically in women or in association with tuberous sclerosis. It manifests as a diffuse cystic lung disease due to infiltration of smooth muscle cells into the pulmonary parenchyma. Genetic mutations within the cells lead to activation of the mammalian target of rapamycin (mTOR) pathway. Diagnosis is based on imaging studies with diffuse thin-walled cysts (**Figure 11**) as well as spontaneous pneumothorax, angiomyolipomas, and elevated vascular endothelial growth factor-D (VEGF-D). Hormonal therapy, which was used in the past, is not effective in altering the disease course. Immunosuppression with sirolimus has demonstrated promise in limiting progression of pulmonary disease in patients with lymphangioleiomyomatosis.

**Occupational Lung Disease  
When to Suspect an Occupational Lung Disease**

Occupational lung diseases affect all aspects of the respiratory tract, from the upper airways to the lower airways and interstitium. Clinical manifestations may include rhinitis, asthma, COPD, constrictive bronchiolitis, and restrictive diseases. Symptom onset following exposure can be acute (reactive airways disease/small airways dysfunction as occurs in acute chlorine gas exposure) as well as prolonged or subacute with a significant latent period (as with asbestosis). Because the clinical presentation of occupational lung disease is highly variable and dependent on the particular exposure, a high index of suspicion is necessary to identify this disorder.



**FIGURE 11.** CT image of a patient with lymphangioleiomyomatosis showing diffuse thin-walled cysts and a right chylothorax.