

CLINICAL THERAPEUTICS

John A. Jarcho, M.D., *Editor*

ERCP for Gallstone Pancreatitis

Evan L. Fogel, M.D., and Stuart Sherman, M.D.

This Journal feature begins with a case vignette that includes a therapeutic recommendation. A discussion of the clinical problem and the mechanism of benefit of this form of therapy follows. Major clinical studies, the clinical use of this therapy, and potential adverse effects are reviewed. Relevant formal guidelines, if they exist, are presented. The article ends with the authors' clinical recommendations.

From the Department of Medicine, Indiana University, Indianapolis. Address reprint requests to Dr. Fogel at Indiana University Health, 550 N. University Blvd., Suite 1602, Indianapolis, IN 46202, or at efogel@iu.edu.

This article was updated on January 9, 2014, at NEJM.org.

N Engl J Med 2014;370:150-7.

DOI: 10.1056/NEJMct1208450

Copyright © 2014 Massachusetts Medical Society.

A 74-year-old man is admitted to the hospital after an acute onset of epigastric pain, which has been unrelenting for 6 hours. He has tachycardia, at a rate of 114 beats per minute; his blood pressure is 140/90 mm Hg, respiratory rate 24 breaths per minute, temperature 37.6°C, and oxygen saturation 92% while he is breathing ambient air. His serum amylase level is 1270 U per liter (normal range, 19 to 86), and his lipase level is 6430 U per liter (normal range, 7 to 59); these levels are consistent with a diagnosis of acute pancreatitis. Other laboratory results at admission include a hematocrit of 47%, white-cell count of 18,000 per cubic millimeter, calcium level of 7.8 mg per deciliter (2.0 mmol per liter), alanine aminotransferase level of 295 IU per liter, aspartate aminotransferase level of 221 IU per liter, alkaline phosphatase level of 217 IU per liter, bilirubin level of 0.9 mg per deciliter (15.4 μmol per liter), glucose level of 240 mg per deciliter (13.3 mmol per liter), blood urea nitrogen level of 47 mg per deciliter (16.8 mmol per liter), and creatinine level of 1.3 mg per deciliter (114.9 μmol per liter). Abdominal ultrasonography reveals gallbladder stones; the common bile duct is 6 mm in diameter, and no intraductal stones are identified. The pancreatitis, which is presumed to have a biliary cause, is predicted to be severe. The consulting gastroenterologist initially favors ongoing supportive therapy but will consider selective endoscopic retrograde cholangiopancreatography (ERCP), depending on the patient's clinical course.

THE CLINICAL PROBLEM

Acute pancreatitis is a common diagnosis worldwide, and more than 240,000 cases are reported annually in the United States alone. Gallstone disease, the most common cause of acute pancreatitis,¹ accounts for approximately 50% of cases in Western countries.

The outcome of acute pancreatitis depends on the severity of the disease. Most patients with gallstone pancreatitis present with mild disease that has a benign course, and they recover quickly with a response to conservative therapy. However, severe pancreatitis associated with clinically significant complications develops in a subgroup of patients. To predict the severity of pancreatitis and to assist in triage of patients (admission to a medical ward or to an intensive care unit), several systems for classifying disease severity have been used²; among them, the Ranson criteria (see Table S1 in the Supplementary Appendix, available with the full text of this article at NEJM.org) and Acute Physiology and Chronic Health Evaluation II criteria (Table S2 in the Supplementary Appendix) are the most common. Because of the relatively low prevalence of severe disease, however, these clinical predictors have a low positive predictive value (43 to 49%) for the development of organ failure or serious complications.³ Our group does not use a formal grading system in the treatment of patients with acute pancreatitis.

Mortality is approximately 5% among all patients with acute pancreatitis and has been as high as 20 to 30% among those with severe cases,^{3,4} although this rate may be declining.⁵ Patients with progressive multisystem organ dysfunction are at highest risk for death, and in one study, mortality among such patients was reported to be higher than 50%.⁶ Deaths that occur within the first 2 weeks after the pancreatitis episode are usually due to the systemic inflammatory response syndrome and multisystem organ failure,⁶ whereas deaths that occur later are typically attributable to complications of necrotizing pancreatitis.

PATHOPHYSIOLOGY AND EFFECTS OF THERAPY

The pathogenesis of gallstone pancreatitis remains unclear. Studies have suggested that a gallstone may compress the septum between the distal biliary and pancreatic ducts, resulting in obstruction of the pancreatic duct, or it may settle in the common channel (the ampulla of Vater), resulting in reflux of bile into the pancreatic duct (Fig. 1A). Both mechanisms may lead to increased pressure in the pancreatic duct. The sequelae of pancreatic-duct obstruction (reflux of pancreatic and biliary secretions, pancreatic-duct hypertension, and aberrant secretion of acinar cells) result in pancreatic-duct injury, with the release of pancreatic enzymes into the glandular interstitium causing pancreatic autodigestion and triggering acute pancreatitis.⁷⁻¹⁰ It appears that the acute onset of ductal obstruction is important, since not all patients with chronic pancreatitis and an obstructed pancreatic duct (and few patients with pancreatic cancer) present with an acute episode of pancreatitis.

It is unclear why most cases of biliary pancreatitis resolve uneventfully, whereas some progress rapidly to the more severe form. A study of experimentally induced pancreatic-duct obstruction in opossums has shown that necrosis is more severe in animals with coexisting pancreatobiliary reflux.¹¹ If a long common channel, which is present in a small percentage of humans, is necessary for bile reflux to occur, this may explain why severe pancreatitis develops in only a minority of patients with bile-duct stones.¹² However, in opossums pancreatitis from pancreatic-duct obstruction may develop even if biliary reflux is prevented

surgically.¹¹ Furthermore, in dogs, perfusion of the pancreas with bile under physiologic conditions does not lead to pancreatitis.¹³

Regardless of the inciting mechanism, at least half of all cases of acute pancreatitis are due to the passage of small stones, usually 5 mm or less in diameter. Gallstones have been recovered in stool from 85 to 95% of patients with acute pancreatitis, as compared with a 10% recovery rate among patients who have symptomatic cholelithiasis without pancreatitis.⁷ Furthermore, surgical series in the 1980s showed a high prevalence of bile-duct stones and impacted ampullary stones (63 to 78%) in patients who underwent surgery within 48 hours after admission to the hospital.^{8,14,15}

It has been proposed that early performance of ERCP with biliary sphincterotomy and removal of the obstructing stone (Fig. 1B and 1C) might ameliorate the course of pancreatitis.¹⁶ Indeed, it is now clear that some patients do require biliary drainage and may not survive without it. However, clinical trials have not consistently shown a benefit of this intervention. The challenge to endoscopists, therefore, is to determine which subgroup of patients will benefit from early ERCP and sphincterotomy.

CLINICAL EVIDENCE

The role and timing of ERCP in patients with acute biliary pancreatitis has long been controversial. Numerous clinical trials¹⁷⁻²⁴ (Table S3 in the Supplementary Appendix) that have addressed this issue typically have evaluated the role of early ERCP with or without endoscopic sphincterotomy, as compared with conservative medical management with or without the selective use of ERCP. The timing of ERCP, inclusion criteria, methods of diagnosing biliary pancreatitis, and assessment of severity differ among studies. Perhaps as a result of these factors, results are conflicting, with some studies suggesting a benefit for selected patients undergoing ERCP and others showing no benefit and perhaps a worse outcome, regardless of the severity of disease (Table S4 in the Supplementary Appendix).

These clinical trials have been reviewed in six meta-analyses and systematic reviews²⁵⁻³⁰ (Tables S5 and S6 in the Supplementary Appendix). The reviews differ with respect to the studies included, largely because of differences in study

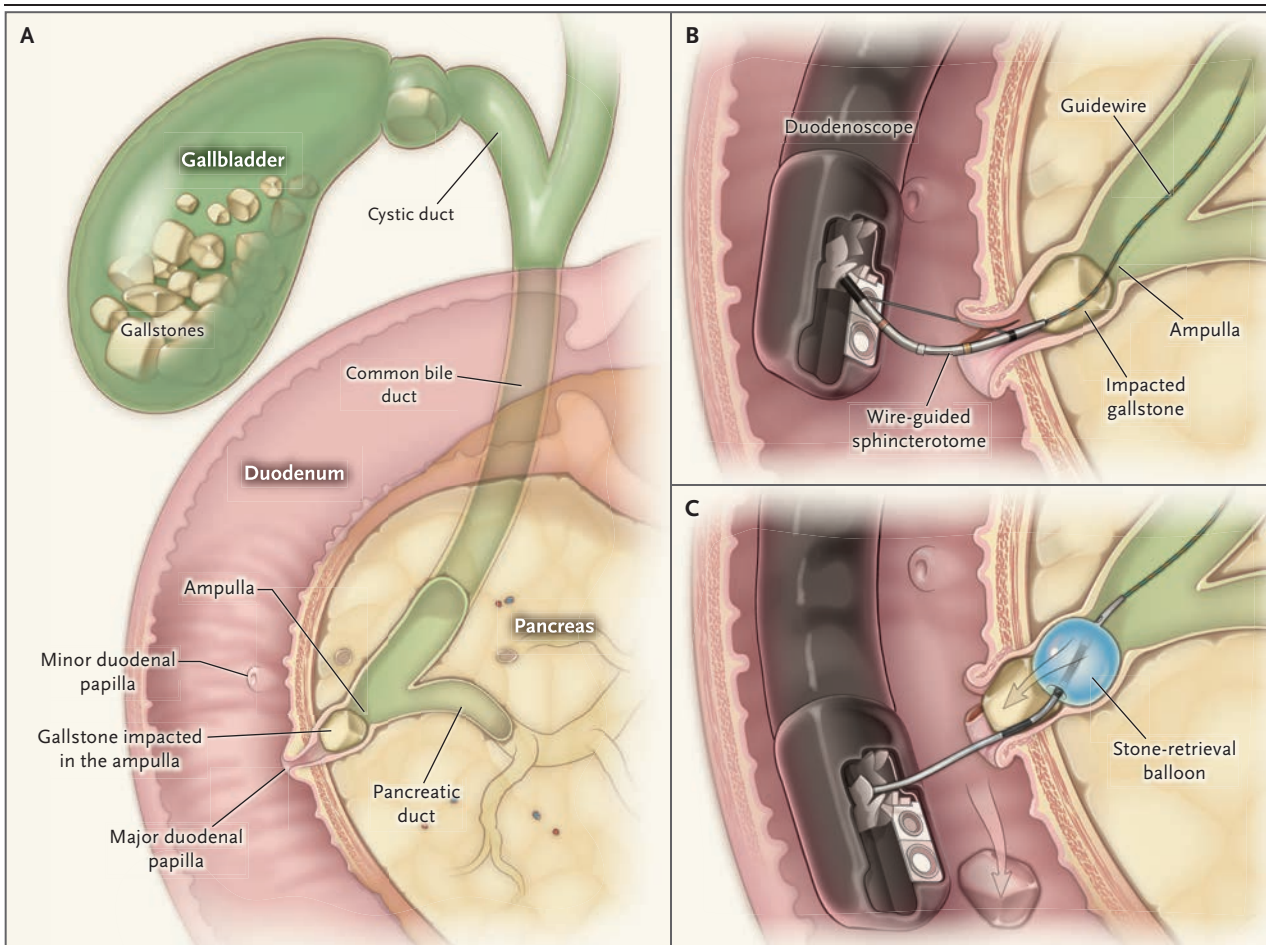


Figure 1. Endoscopic Retrograde Cholangiopancreatography (ERCP) in the Management of Biliary Pancreatitis.

As shown in Panel A, biliary pancreatitis occurs when a gallstone becomes impacted in the ampulla, resulting in obstruction of the common bile duct and the pancreatic duct and reflux of bile into the pancreatic duct. As shown in Panel B, ERCP is performed by means of a side-viewing duodenoscope, with a channel to allow for the passage of instruments. A wire-guided sphincterotome cuts the biliary sphincter with the use of electrocautery. As shown in Panel C, a retrieval balloon can then be used to sweep the duct and remove the stone.

design and inclusion and exclusion criteria. The consensus is that in the absence of cholangitis and biliary obstruction, performance of early ERCP (within 24 to 72 hours after admission to the hospital) does not lead to a reduction in mortality or in local or systemic complications. Furthermore, the results are not dependent on the predicted severity of pancreatitis. Data provide support for the performance of ERCP in patients with biliary obstruction or cholangitis.

CLINICAL USE

Most patients with biliary pancreatitis, regardless of the predicted severity, do not benefit from

ERCP, with or without sphincterotomy. For initial treatment, we proceed with ERCP within 24 to 48 hours after presentation in patients with acute disease and symptoms or signs of coexisting cholangitis (e.g., fever, jaundice, and sepsis) or persistent biliary obstruction (a conjugated bilirubin level >5 mg per deciliter [$86 \mu\text{mol}$ per liter]). Intervention with ERCP is also considered in patients who have clinical deterioration (e.g., worsening pain, leukocytosis, and a change in vital signs) and increasing liver-enzyme levels. Finally, if radiologic imaging such as abdominal ultrasonography or computed tomography shows a stone in the common bile duct, ERCP should be performed. An unstable medical condition that

precludes safe moderate sedation is an absolute contraindication to ERCP; relative contraindications have typically included altered postsurgical anatomical features that prevent endoscopic access to the major papilla and clinically significant coagulopathy (Table 1).

When the decision is made to proceed with ERCP, several clinical issues need to be addressed. For patients with cholangitis or biliary obstruction in whom absorption of vitamin K may be impaired, the prothrombin time, international normalized ratio (INR), or both should be checked and corrected as necessary. An INR below 1.5 is preferred, as well as a platelet count greater than 75,000 per cubic millimeter, particularly when performance of a sphincterotomy is anticipated. Intravenous fluid resuscitation at a rate of more than 250 ml per hour for at least the initial 24 hours after admission should be considered, since avoidance of intravascular depletion appears to improve the outcome in patients with acute pancreatitis.³¹ The patient should receive nothing by mouth; if enteral feeding has been used, it should be discontinued well in advance of the procedure (i.e., 6 to 8 hours beforehand). Patients with biliary obstruction require antibiotic prophylaxis before ERCP. The use of a quinolone or cephalosporin is favored, since gram-negative bacilli are most commonly identified when infection complicates this procedure.

Since fluoroscopy is required to visualize the ductal structures during ERCP, the procedure can be performed in the radiology department or in the endoscopy suite if it has a separate fluoroscopy unit available. The procedure is performed with the patient in the prone position, although the left lateral or even supine position may be necessary in some circumstances (e.g., in patients who are morbidly obese and in those with large-volume ascites or an abdominal wound or drains). Personnel in the procedure room include the endoscopist, an anesthesiologist, a radiology technician, and a nurse who assists with the technical aspects of the procedure.

ERCP is performed with the use of a side-viewing duodenoscope (see the video, available at NEJM.org.) An instrument channel allows for passage of the catheter, sphincterotome, and other accessories through the duodenoscope, and an elevator allows for deflection of the instruments. The duodenoscope is passed through the patient's mouth to the descending duodenum. Biliary can-

Table 1. Indications and Contraindications for ERCP in Patients with Acute Biliary Pancreatitis.

Indications

Suspected bile-duct stones as the cause of pancreatitis established clinically, and one of the following:

Cholangitis (fever, jaundice, sepsis)

Persistent biliary obstruction (conjugated bilirubin level >5 mg/dl [86 μ mol per liter])

Clinical deterioration (worsening pain, increasing white-cell count, worsening vital signs)

Stone detected in the common bile duct on imaging

Contraindications

Absolute

Unstable medical condition precluding safe administration of moderate sedation or general anesthesia

Decision by competent patient not to provide consent for the procedure

Endoscopist with inadequate training in ERCP

Relative (may be overcome)

Anatomical condition (gastroduodenal disease or surgical alteration) that would impede endoscopic access to the major papilla; may be overcome in the case of a long Roux limb, for example, with the use of modified equipment and accessories

Clinically significant or uncorrectable coagulopathy; may be overcome, since a biliary stent can be placed without need for sphincterotomy

nulation is then attempted, with care taken to avoid or minimize entry into the pancreas. Cannulation with a wire-guided sphincterotome is typically attempted (Fig. 1B) in anticipation of a sphincterotomy.

Once successful cannulation is achieved, contrast material is injected into the biliary tree, and digital fluoroscopic images are captured. If cholangitis is suspected, bile is aspirated before injection of contrast material in order to decompress the biliary tree and minimize the risk of dissemination of infection. Bile may be obtained for culture to aid in the choice of antibiotic coverage.

If a stone is identified, the biliary orifice is opened with the use of a sphincterotome (Fig. 1B). Electrocautery with a wire from the sphincterotome is used to cut the biliary sphincter segment. Tension is applied to the wire to create a curve in the tip of the catheter; this exposes the wire and allows for adjustment. The nurse assistant controls the amount of tension applied to the wire by varying the traction on the handle of the sphincterotome, while the endoscopist controls the cautery by using a foot pedal attached to an electrical generator.

Small-to-medium-size stones (≤ 1 cm in diameter) can usually be removed easily with a retrieval



A video showing ERCP is available at NEJM.org

balloon, which is used to sweep the bile duct, removing the stone (or stones) below (Fig. 1C). Retrieval of larger stones may require the use of a basket-tipped catheter, which allows for the greater force needed to pull the stone through the biliary orifice. Occasionally, the tip of an impacted stone can be seen protruding from the biliary orifice of a bulging major papilla. In these cases, the experienced endoscopist may consider the use of a needle-knife sphincterotome, which deploys a short, bare wire that is used to cut directly over the impacted stone, facilitating its removal. Advanced techniques such as stone fragmentation (lithotripsy) are sometimes necessary to remove large stones, although further balloon dilation of the biliary orifice after sphincterotomy may suffice.

Placement of a bile-duct stent during ERCP may be useful in several circumstances. If complete stone removal is not accomplished during a single procedure, if there are additional stones in the gallbladder with a patent cystic duct (unless cholecystectomy is planned within the next several days), or if active cholangitis is present, stent placement may be considered to facilitate bile drainage. A second ERCP procedure will then be necessary for stent removal and clearance of any remaining stones.

The ERCP procedure time ranges from 20 minutes to more than 1 hour, depending on the ease of cannulation, the number and size of the stones, the skill level of the endoscopist, and other factors. After completion of the procedure, the patient is monitored in the recovery area, initially to assess cardiopulmonary stability and for signs of procedural complications. When discharge criteria are met (usually within 1 to 2 hours after the procedure), the patient is returned to the hospital ward for ongoing care.

If a ductal stone is not visualized during ERCP and there is strong clinical suspicion of a stone, an empirical biliary sphincterotomy is performed. Microlithiasis can result in an attack of pancreatitis that is as severe as that associated with a larger stone, and small stones may not be seen on fluoroscopy. Furthermore, some patients with acute biliary pancreatitis may not be considered candidates for cholecystectomy because of coexisting medical illnesses. A biliary sphincterotomy will prevent recurrent episodes of biliary pancreatitis without the risks associated with operative intervention in patients who are unable to undergo surgery because of advanced age or disease,³²⁻³⁴ and in pregnant patients.^{35,36}

Facility and hospital costs for ERCP vary according to the institution. In 2012, the Medicare physician reimbursement for an ERCP with sphincterotomy and stone removal was \$568. Placement of a stent increased this amount to \$651 and necessitated a second procedure for stent removal (and possibly further stone removal). Medicare paid approximately \$350 for anesthesiology costs, \$600 for recovery-room costs, and \$250 for pharmacy costs.

ADVERSE EFFECTS

Pancreatitis is the most common complication after ERCP, with frequency estimates in the range of 2 to 8% among low-risk patients, such as those with uncomplicated choledocholithiasis.³⁷ Concern about exacerbating pancreatitis in patients with acute biliary pancreatitis delayed the introduction of ERCP as a therapeutic procedure until the 1980s. The trial by Neoptolemos et al.¹⁷ was one of the first to show that ERCP could be performed safely by an expert endoscopist in patients with acute biliary pancreatitis. However, none of the randomized trials¹⁷⁻²⁴ specifically assessed post-ERCP pancreatitis as a complication, probably because of the difficulty in confirming this diagnosis in patients with established acute biliary pancreatitis.

Other complications of ERCP include bleeding (typically after sphincterotomy), ductal or intestinal perforation, infection, and cardiopulmonary events. When sphincterotomy is not performed, bleeding and perianastomotic perforations should not occur. However, perforations of the pancreatic duct, the bile duct, or both with wire as well as intestinal perforations due to trauma from the duodenoscope or another instrument (particularly in patients with anatomical alterations after surgery) can occur without a sphincterotomy. Post-ERCP bleeding has been reported in five randomized trials,^{17,18,20,22,24} with no significant difference in event rates between the patients assigned to early routine ERCP and those assigned to a conservative treatment strategy (2.6% and 1.4%, respectively; $P=0.40$). Postprocedure perforation was assessed in two trials,^{17,20} with no cases identified.

The trial by Fölsch and colleagues²⁰ showed an increased incidence of respiratory failure in the ERCP group as compared with the conservative-treatment group (15 of 126 patients [11.9%] vs. 5 of 112 patients [4.5%]; odds ratio, 5.16; 95%

confidence interval, 1.63 to 22.9; $P=0.03$). Although hypoxemia is not uncommon in patients with pancreatitis, early ERCP did not lead to this complication in the other randomized trials. The reason for the increase in the incidence of respiratory failure in the trial by Fölsch and colleagues remains unclear.

AREAS OF UNCERTAINTY

Early meta-analyses²⁶⁻²⁸ suggested that patients with severe biliary pancreatitis benefited from early intervention with ERCP, with or without sphincterotomy. However, subsequent reviews^{25,29,30} have not confirmed this benefit in patients who do not have coexisting cholangitis. In patients who have biliary pancreatitis without jaundice, both endoscopic ultrasonography^{38,39} and magnetic resonance cholangiopancreatography⁴⁰⁻⁴² are highly accurate in predicting persistent choledocholithiasis, and these tests allow for more appropriate use of ERCP. Indeed, an increasingly favored approach is to perform endoscopic ultrasonography followed by ERCP (while the patient is under the same sedation) only if bile-duct stones are detected. Further studies are needed to determine whether these imaging techniques may obviate the need for intraoperative cholangiography during a subsequent cholecystectomy.

The question of whether all patients with gallbladder stones and biliary pancreatitis should undergo elective cholecystectomy after a biliary sphincterotomy remains controversial. In a randomized trial addressing this question, 120 patients who had undergone ERCP with sphincterotomy and stone extraction were assigned to either laparoscopic cholecystectomy within 6 weeks after the initial procedure or a conservative wait-and-see approach.⁴³ The wait-and-see approach was associated with more biliary-related events, the need for repeat ERCP in some cases, more postoperative complications, and longer hospital stays. We recommend laparoscopic cholecystectomy in patients who are able to undergo surgery after clearance of the bile duct. If ERCP and sphincterotomy are not performed during the initial episode of pancreatitis, surgery should be performed once the acute symptoms have resolved. An intraoperative cholangiogram should be obtained during cholecystectomy, particularly if a preoperative sphincterotomy has not been performed.

In a patient who presents with acute biliary pancreatitis after cholecystectomy, a decision

needs to be made regarding whether to perform ERCP. If the patient continues to have abdominal pain and persistently elevated levels of liver enzymes, despite apparent resolution of the pancreatitis, proceeding directly to ERCP is reasonable. If the patient has recovered from the episode of pancreatitis with substantial improvement in (or normalization of) liver-enzyme levels, we perform an evaluation with either magnetic resonance cholangiopancreatography or endoscopic ultrasonography and proceed to ERCP only if choledocholithiasis is identified.

GUIDELINES

Guidelines from the United Kingdom, published in 2005, support early ERCP (within 72 hours after admission to the hospital) in all patients with predicted or actual severe biliary pancreatitis.⁴⁴ However, these recommendations were based on the findings of earlier randomized trials¹⁷⁻²⁰ as well as reviews by Sharma and Howden²⁶ and Ayub et al.²⁷ As noted above, subsequent studies have shown a benefit only in patients with coexisting cholangitis. In 2007, the American Gastroenterological Association published a position statement concluding that the role of routine ERCP in severe biliary pancreatitis remains controversial.⁴⁵ Urgent ERCP (within 24 hours after admission) was recommended, however, in patients with cholangitis, and early ERCP (within 72 hours after admission) was recommended if suspicion of persistent bile-duct stones remained high. Recent guidelines published by the American College of Gastroenterology suggest that urgent ERCP (within 24 hours after admission) is indicated in patients with biliary pancreatitis who have concurrent acute cholangitis, but it is not needed in most patients who do not have evidence of ongoing biliary obstruction.⁴⁶

RECOMMENDATIONS

The patient described in the vignette is a 74-year-old man presenting with acute pancreatitis. The combination of a serum alanine aminotransferase level of 295 U per liter (7 times as high as the normal level) and cholelithiasis identified on abdominal ultrasonography is highly suggestive of a biliary cause. The clinical picture presented is not suggestive of coexisting ascending cholangitis or biliary obstruction (i.e., the serum bilirubin level is normal and the bile duct is normal in diame-

ter). This patient should be treated conservatively with aggressive intravenous fluid resuscitation, intravenous analgesics, and antiemetic agents. In this case, we would not routinely proceed with early ERCP (within 72 hours after admission). However, ERCP would be considered if the patient's clinical condition deteriorated, particularly if he had increasing levels of serum liver enzymes, and a biliary sphincterotomy would be performed if a stone in the common bile duct was identified. To reduce the risk of

future biliary events, we would recommend cholecystectomy during this same hospital stay if the patient was not at high surgical risk once his pancreatitis resolved.

Dr. Fogel reports receiving lecture fees from Olympus; and Dr. Sherman, consulting fees from Repligen and lecture fees from Cook, Olympus, and Boston Scientific. No other potential conflict of interest relevant to this article was reported.

Disclosure forms provided by the authors are available with the full text of this article at NEJM.org.

We thank Ms. Sophie Zhou for her translation of the article by Tang et al.²⁴ into English.

REFERENCES

- Attasaranya S, Fogel EL, Lehman GA. Choledocholithiasis, ascending cholangitis and gallstone pancreatitis. *Med Clin North Am* 2008;92:925-60.
- Mounzer R, Langmead CJ, Wu BU, et al. Comparison of existing clinical scoring systems to predict persistent organ failure in patients with acute pancreatitis. *Gastroenterology* 2012;142:1476-82.
- Banks PA, Freeman ML. Practice guidelines in acute pancreatitis. *Am J Gastroenterol* 2006;101:2379-400.
- Pitchumoni CS, Patel NM, Shah P. Factors influencing mortality in acute pancreatitis: can we alter them? *J Clin Gastroenterol* 2005;39:798-814.
- Howard TJ, Patel JB, Zyromski N, et al. Declining morbidity and mortality rates in the surgical management of pancreatic necrosis. *J Gastrointest Surg* 2007;11:43-9.
- Buter A, Imrie CW, Carter CR, Evans S, McKay CJ. Dynamic nature of early organ dysfunction determines outcome in acute pancreatitis. *Br J Surg* 2002;89:298-302.
- Acosta JM, Ledesma CL. Gallstone migration as a cause of acute pancreatitis. *N Engl J Med* 1974;290:484-7.
- Acosta JM, Pellegrini CA, Skinner DB. Etiology and pathogenesis of acute biliary pancreatitis. *Surgery* 1980;88:118-25.
- Wang GJ, Gao CF, Wei D, Wang C, Ding SQ. Acute pancreatitis: etiology and common pathogenesis. *World J Gastroenterol* 2009;15:1427-30.
- Lightner AM, Kirkwood KS. Pathophysiology of gallstone pancreatitis. *Front Biosci* 2001;6:E66-76.
- Lerch MM, Saluja AK, Rünzi M, Dawra R, Saluja M, Steer ML. Pancreatic duct obstruction triggers acute necrotizing pancreatitis in the opossum. *Gastroenterology* 1993;104:853-61.
- Pasricha P. Of opie, opossums, and others: emergent ERCP for gallstone pancreatitis. *Gastroenterology* 1997;113:1040-2.
- White TT, Magee DF. Perfusion of the dog pancreas with bile without production of pancreatitis. *Ann Surg* 1960;151:245-50.
- Kelly TR. Gallstone pancreatitis: the timing of surgery. *Surgery* 1980;88:345-50.
- Stone HH, Fabian TC, Dunlop WE. Gallstone pancreatitis: biliary tract pathology in relation to time of operation. *Ann Surg* 1981;194:305-12.
- Acosta JM, Rossi R, Galli OM, Pellegrini CA, Skinner DB. Early surgery for acute gallstone pancreatitis: evaluation of a systematic approach. *Surgery* 1978;83:367-70.
- Neoptolemos JP, Carr-Locke DL, London NJ, Bailey IA, James D, Fossard DP. Controlled trial of urgent endoscopic retrograde cholangiopancreatography and endoscopic sphincterotomy versus conservative treatment for acute pancreatitis due to gallstones. *Lancet* 1988;2:979-83.
- Fan S-T, Lai ECS, Mok FPT, Lo CML, Zheng SS, Wong J. Early treatment of acute biliary pancreatitis by endoscopic papillotomy. *N Engl J Med* 1993;328:228-32.
- Nowak A, Nowakowska-Dulawa E, Marek TA, Rybicka J. Final results of the prospective, randomized, controlled study on endoscopic sphincterotomy versus conventional management in acute biliary pancreatitis. *Gastroenterology* 1995;108:A380. abstract.
- Fölsch UR, Nitsche R, Lütke R, Hilgers RA, Creutzfeldt W. Early ERCP and papillotomy compared with conservative treatment for acute biliary pancreatitis. *N Engl J Med* 1997;336:237-42.
- Oría A, Cimmino D, Ocampo C, et al. Early endoscopic intervention versus early conservative management in patients with acute gallstone pancreatitis and biliopancreatic obstruction: a randomized clinical trial. *Ann Surg* 2007;245:10-7.
- Zhou MQ, Li NP, Lu RD. Duodenoscopy in treatment of acute gallstone pancreatitis. *Hepatobiliary Pancreat Dis Int* 2002;1:608-10.
- Chen P, Hu B, Wang C, Kang Y, Jin X, Tang C. Pilot study of urgent endoscopic intervention without fluoroscopy on patients with severe acute biliary pancreatitis in the intensive care unit. *Pancreas* 2010;39:398-402.
- Tang Y, Xu Y, Liao G. Effect of early endoscopic treatment for patients with severe acute biliary pancreatitis. *Chinese J Gen Surg* 2010;19:801-4.
- Tse F, Yuan Y. Early routine endoscopic retrograde cholangiopancreatography strategy versus early conservative management strategy in acute gallstone pancreatitis. *Cochrane Database Syst Rev* 2012;5:CD009779.
- Sharma VK, Howden CW. Metaanalysis of randomized controlled trials of endoscopic retrograde cholangiography and endoscopic sphincterotomy for the treatment of acute biliary pancreatitis. *Am J Gastroenterol* 1999;94:3211-4.
- Ayub K, Imada R, Slaviv J. Endoscopic retrograde cholangiopancreatography in gallstone-associated acute pancreatitis. *Cochrane Database Syst Rev* 2004;4:CD003630.
- Moretti A, Papi C, Aratari A, et al. Is early endoscopic retrograde cholangiopancreatography useful in the management of acute biliary pancreatitis? A meta-analysis of randomized controlled trials. *Dig Liver Dis* 2008;40:379-85.
- Petrov MS, van Santvoort HC, Besselink MGH, van der Heijden GJ, van Erpecum KJ, Gooszen HG. Early endoscopic retrograde cholangiopancreatography versus conservative management in acute biliary pancreatitis without cholangitis: a meta-analysis of randomized trials. *Ann Surg* 2008;247:250-7.
- Uy MC, Daez MLO, Sy PP, Banez VP, Espinosa WZ, Talingdan-Te MC. Early ERCP in acute gallstone pancreatitis without cholangitis: a meta-analysis. *JOP* 2009;10:299-305.
- Wall I, Badalov N, Baradaran R, Iswara K, Li JJ, Tenner S. Decreased mortality in acute pancreatitis related to early aggressive hydration. *Pancreas* 2011;40:547-50.
- Siegel JH, Veerappan A, Cohen SA, Kasmin FE. Endoscopic sphincterotomy for biliary pancreatitis: an alternative to cholecystectomy in high-risk patients. *Gastrointest Endosc* 1994;40:573-5.
- Wellbourn CR, Beckly DE, Eyre-Brook

- IA. Endoscopic sphincterotomy without cholecystectomy for gall stone pancreatitis. *Gut* 1995;37:119-20.
34. Uomo G, Manes G, Laccetti M, Cavalera A, Rabitti PG. Endoscopic sphincterotomy and recurrence of acute pancreatitis in gallstone patients considered unfit for surgery. *Pancreas* 1997;14:28-31.
35. Swisher SG, Hunt KK, Schmit PJ, Hiyama DT, Bennion RS, Thompson JE. Management of pancreatitis complicating pregnancy. *Am Surg* 1994;60:759-62.
36. Barthel JS, Chowdhury T, Miedema BW. Endoscopic sphincterotomy for the treatment of gallstone pancreatitis during pregnancy. *Surg Endosc* 1998;12:394-9.
37. Freeman ML, Nelson DB, Sherman S, et al. Complications of endoscopic biliary sphincterotomy. *N Engl J Med* 1996;335:909-18.
38. Zhan X, Guo X, Chen Y, et al. EUS in exploring the etiology of mild acute biliary pancreatitis with a negative finding of biliary origin by conventional radiological methods. *J Gastroenterol Hepatol* 2011;26:1500-3.
39. Stabuc B, Drobne D, Ferkolj I, et al. Acute biliary pancreatitis: detection of common bile duct stones with endoscopic ultrasound. *Eur J Gastroenterol Hepatol* 2008;20:1171-5.
40. Srinivasa S, Sammour T, McEntee B, Davis N, Hill AG. Selective use of magnetic resonance cholangiopancreatography in clinical practice may miss choledocholithiasis in gallstone pancreatitis. *Can J Surg* 2010;53:403-7.
41. Telem DA, Bowman K, Hwang J, Chin EH, Nguyen SQ, Divino CM. Selective management of patients with acute biliary pancreatitis. *J Gastrointest Surg* 2009;13:2183-8.
42. Mofidi R, Lee AC, Madhavan KK, Garden OJ, Parks RW. The selective use of magnetic resonance cholangiopancreatography in the imaging of the axial biliary tree in patients with acute gallstone pancreatitis. *Pancreatology* 2008;8:55-60.
43. Boerma D, Rauws EA, Keulemans YC, et al. Wait-and-see policy or laparoscopic cholecystectomy after endoscopic sphincterotomy for bile-duct stones: a randomised trial. *Lancet* 2002;360:761-5.
44. Working Party of the British Society of Gastroenterology, Association of Surgeons of Great Britain and Ireland, Pancreatic Society of Great Britain and Ireland, Association of Upper GI Surgeons of Great Britain and Ireland. UK guidelines for the management of acute pancreatitis. *Gut* 2005;54:Suppl 3:iii1-iii9.
45. Forsmark CE, Baillie J. AGA Institute technical review on acute pancreatitis. *Gastroenterology* 2007;132:2022-44.
46. Tenner S, Baillie J, DeWitt J, Vege SS. American College of Gastroenterology guideline: management of acute pancreatitis. *Am J Gastroenterol* 2013;108:1400-15.

Copyright © 2014 Massachusetts Medical Society.

JOURNAL ARCHIVE AT NEJM.ORG

Every article published by the *Journal* is now available at NEJM.org, beginning with the first article published in January 1812. The entire archive is fully searchable, and browsing of titles and tables of contents is easy and available to all. Individual subscribers are entitled to free 24-hour access to 50 archive articles per year. Access to content in the archive is available on a per-article basis and is also being provided through many institutional subscriptions.