

## BEST PRACTICE

## Acute glomerulonephritis

C S Vinen, D B G Oliveira

Postgrad Med J 2003;79:206–213

Glomerulonephritis is an important cause of renal failure thought to be caused by autoimmune damage to the kidney. While each type of glomerulonephritis begins with a unique initiating stimulus, subsequent common inflammatory and fibrotic events lead to a final pathway of progressive renal damage. In this article the different forms of inflammatory glomerulonephritis and their diagnosis are discussed. In a review of therapy both immediate life saving treatment given when glomerulonephritis causes acute renal failure and more specific treatments designed to modify the underlying mechanisms of renal injury are considered.

lung and glomerulus.<sup>2</sup> In post-streptococcal glomerulonephritis antibodies are formed not to an endogenous antigen but to an exogenous streptococcal antigen planted in the glomerulus at the time of infection.<sup>3</sup> In systemic lupus erythematosus and IgA nephropathy, the antigen antibody reaction occurs not only in situ in the glomerulus but also systemically with subsequent trapping of complexes in the kidney. Finally in the glomerulonephritis seen in small vessel vasculitis, cellular rather than humoral immune responses are thought to be stimulated, with inflammation often originating in organs distant to the kidney with a subsequent renal influx of T-cells and macrophages as crescentic glomerulonephritis evolves.

**G**lomerulonephritis is an important cause of renal impairment accounting for 10%–15% of cases of end stage renal failure in the USA, following only diabetes and hypertension in importance.<sup>1</sup> In defining acute glomerulonephritis, we have chosen to discuss those glomerular diseases that may present with a nephritic syndrome—that is with haematuria, proteinuria, and impaired renal function together with hypertension, fluid overload, and oedema. Their pathology involves intraglomerular inflammation and cellular proliferation with secondary renal impairment over days to weeks. This definition excludes glomerular diseases without cell proliferation or nephritic presentations, such as minimal change disease, membranous nephropathy, and focal segmental glomerulosclerosis that can, none the less, chronically compromise renal function. In primary glomerulonephritis, disease is almost entirely restricted to the kidneys (as in IgA nephropathy or post-streptococcal glomerulonephritis) while in secondary glomerulonephritis it occurs in association with more diffuse inflammation (as in systemic lupus erythematosus or systemic vasculitis). Prompt diagnosis of glomerulonephritis is vital as patients with even mildly impaired renal function, hypertension, and urinary abnormalities may rapidly lose kidney function if not treated urgently.

Although our understanding of the causes of glomerulonephritis is still at a basic level, inflammation is thought to be autoimmune mediated and involve both cellular and humoral immune systems. In each case a unique initiating stimulus (occurring by one of at least four different mechanisms) is followed by a common pathway of inflammatory and subsequently fibrotic events. In antiglomerular basement membrane disease, patients produce antibodies that react directly with the specialised basement membranes of the

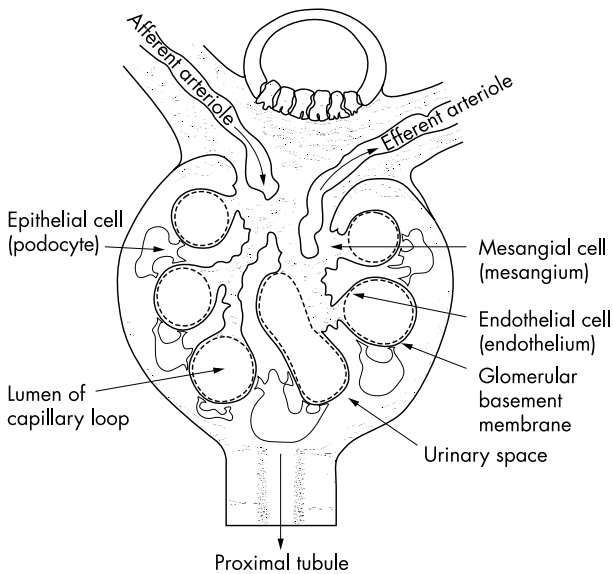
Whatever the initial events, common inflammatory pathways follow with activation of the coagulation and complement cascades and production of proinflammatory cytokines.<sup>4</sup> Activation of complement components leads to chemotaxis of inflammatory cells and cell lysis (via the membrane attack complex). The coagulation cascade leads to fibrin deposition. Cellular proliferation of parietal epithelial cells in Bowman's space together with an influx of inflammatory cells such as macrophages and neutrophils results in acute glomerular crescent formation. Cytokine release leads to activation of the glomerular cells themselves and a change in endogenous cell phenotype results in cell proliferation, overproduction of proteases and oxidants, and laying down of extracellular matrix with subsequent fibrosis, perhaps stimulated by factors such as platelet derived growth factor and transforming growth factor beta. Failure of apoptosis (the normal mechanism allowing resolution of inflammation) is also important. Finally in a chronic phase of damage, haemodynamic alterations lead to hyperfiltration and intraglomerular hypertension<sup>5</sup> with subsequent development of glomerular sclerosis and chronic interstitial damage. Thus a process that is initially inflammatory with the potential to resolve may progress to fibrosis and irreversible scarring. This dynamic picture may partly explain why in post-streptococcal glomerulonephritis where antigen is rapidly cleared, even acute renal failure can be expected to resolve spontaneously. By contrast in hepatitis C associated mesangiocapillary glomerulonephritis (MCGN) where viral infection is chronic, antigen cannot be cleared and renal damage may chronically progress.

**Abbreviations:** ACE, angiotensin converting enzyme; ANCA, antineutrophil cytoplasmic antibodies; HSP, Henoch-Schönlein purpura; MCGN, mesangiocapillary glomerulonephritis; RPGN, rapidly progressive glomerulonephritis; WHO, World Health Organisation

See end of article for authors' affiliations

Correspondence to:  
Professor David Oliveira,  
Department of Renal  
Medicine, St George's  
Hospital Medical School,  
Cranmer Terrace, London  
SW17 0RE, UK;  
d.oliveira@sghms.ac.uk

Submitted 17 May 2002  
Accepted  
5 November 2002



**Figure 1** Section through a normal renal glomerulus. Blood is carried in to the glomerulus by an afferent arteriole and leaves by the efferent arteriole. Capillary loops that emerge from the vascular pole are supported by stalks of mesangial cells. On entering the lumen of a capillary loop, blood is filtered through a barrier consisting of a fenestrated endothelial layer, the glomerular basement membrane, and an epithelial layer. Urine emerges in to the urinary space and passes in to the proximal tubule.

To understand the histology of glomerulonephritis, we need to revisit the basic structure of the normal kidney (see fig 1). Inflammatory, proliferative, and fibrotic changes may affect specific cells of the kidney differently or may result in more global changes with particular patterns resulting in a spectrum of clinical presentations. In table 1, we have attempted to summarise the complex nomenclature that surrounds glomerulonephritis by naming each disease, describing its common renal clinical presentation and explaining its underlying histological lesion. In table 2 we have focused purely on clinical aspects which may aid rapid diagnosis. Renal biopsies are vital both in defining a diagnosis, and also in offering prognostic information by differentiating acute reversible damage from chronically scarred non-viable kidney which does not justify the risks of potentially toxic therapy. Although current treatments are, at best, crude, with greater understanding of pathological events we hope to design more specific therapy both to limit acute damage, and to prevent progression to chronic scarring with its inevitable decline in renal function.

### POST-INFECTIOUS ENDOCAPILLARY GLOMERULONEPHRITIS

Post-streptococcal glomerulonephritis is the best known example of endocapillary glomerulonephritis, the most common form of acute glomerulonephritis seen after some bacterial, viral, fungal, and parasitic infections. Although this pattern of glomerular injury after a streptococcal infection remains an important cause of acute renal failure in the developing world, in Europe and the USA this lesion is increasingly seen in infections such as endocarditis after intravenous drug abuse. In post-streptococcal glomerulonephritis, children are usually affected with a male preponderance.<sup>6</sup> It can follow pharyngitis (commonly in winter) or skin infections (commonly in summer) with a  $\beta$ -haemolytic nephritogenic strain of streptococcus (often type 12) with the glomerulonephritis occurring one to 12 weeks after initial infection. It affects up to 15% of those infected, although many cases are subclinical and self resolving. In

children most severely affected, presentation is with the classic nephritic picture of puffy eyelids, facial oedema, hypertension, and dark scanty urine with microscopic haematuria and proteinuria.

The pathology is that of a planted antigen where a streptococcal component is deposited in the glomerulus during infection.<sup>3</sup> Subsequent production of antibody by the host produces in situ immune complex formation which alters the permeability of the glomerular basement membrane and allows subsequent deposition of further pre-formed immune complexes. In addition streptococcal antigen may cross react with glomerular structures or directly activate complement with subsequent attraction of inflammatory cells.<sup>7, 8</sup> Immune deposits initiate a diffuse proliferative glomerulonephritis particularly affecting mesangial and endothelial cells. Immunostaining shows C3 in the mesangium and along capillary walls with accompanying IgG.

Serology may show raised antistreptolysin antibody titres but its absence does not exclude the diagnosis as many nephritogenic strains do not produce streptolysin. Low C3 levels with normal C4 levels (due to alternative pathway activation) are seen acutely but should have returned to normal within two months.

### MESANGIOPROLIFERATIVE GLOMERULONEPHRITIS/ IGA NEPHROPATHY

IgA nephropathy is the commonest of all glomerulonephritides world wide. Thus although only 4%–13% of patients present with acute nephritis (the commoner presentation being with micro or macroscopic haematuria), this still represents a considerable number of cases.<sup>9</sup> Peak presentation is during the second and third decades showing a 2:1 male preponderance with attacks sometimes after infection (particularly pharyngitis<sup>10, 11</sup>). The disease shows great geographic variation and is more common in the Western Pacific rim and in Asia (accounting for 50% of primary glomerular disease in Japan) but is rare in black populations.<sup>1</sup>

IgA nephropathy is the classic mesangioproliferative glomerulonephritis where cellular proliferation may be either diffuse or focal but affects predominantly the mesangium. Immunofluorescence shows paramesangial deposition of IgA (with some IgG and IgM) together with alternative pathway complement components, while electron microscopy shows mesangial dense deposits. Polymeric IgA1 is deposited<sup>12</sup> in the kidney after overproduction of systemic IgA1 polymers (possibly in response to infection) together with impaired clearance through both the hepatic and the myeloid routes. In addition abnormal glycosylation of IgA may make it more prone to self aggregate and form immune complexes with affinity for the mesangium.<sup>12</sup> The disease is associated with a raised serum concentrations of IgA in 50% of patients, but serum complement levels are normal as complement activation is restricted to the kidneys alone.<sup>13</sup>

### HENOCH-SCHÖNLEIN PURPURA

The renal lesion of Henoch-Schönlein purpura (HSP) is almost identical to that of the more severe variants of IgA nephropathy. However, as a small vessel vasculitis, HSP also has the systemic features of a purpuric rash largely affecting the lower limbs, arthritis or arthralgia, and abdominal pain sometimes in association with rectal bleeding. The disease is most commonly seen in those less than 20 years of age. Renal involvement is not always present initially but its incidence increases with time and is more common in older children who have associated abdominal pain and a persisting rash.<sup>14</sup> Renal involvement can also occur in adults where it is thought to carry a worse prognosis. Although haematuria and proteinuria are the most common renal presentations, 8% of patients will have an acute nephritis and up to 29% may present with a combined nephritic and nephrotic picture.<sup>9</sup>

**Table 1** The classification of acute glomerulonephritis by disease, renal presentation, and histological lesion (where the nephritic syndrome is a relatively rare presentation, the more usual clinical presentation is given in bold type)

Disease	Possible clinical renal presentations	Most common histological lesion
<b>Postinfectious glomerulonephritis</b> (Historically post-streptococcal but also seen with other bacterial, viral and parasitic infections)	Nephritic syndrome, haematuria, proteinuria	Endocapillary glomerulonephritis—a diffuse proliferative glomerulonephritis especially affecting mesangial and endothelial cells possibly provoked by in situ immune complex deposition due to a planted streptococcal antigen
<b>IgA nephropathy</b>	Nephritic syndrome <b>Macroscopic/microscopic haematuria</b>	Mesangioproliferative glomerulonephritis—a focal or diffuse cellular proliferation affecting predominantly the mesangium possibly stimulated by polymeric IgA deposition
<b>Henoch-Schönlein purpura</b>	Nephritic syndrome, haematuria, proteinuria, nephrotic syndrome	Mesangial cell proliferation may be associated with glomerular crescents, capillary necrosis and leucocytoclastic vasculitis possibly due to subtle differences in size of IgA deposits
<b>Wegener's granulomatosis, microscopic polyangiitis, idiopathic crescentic glomerulonephritis</b>	Rapidly progressive glomerulonephritis, nephritic syndrome	A focal or diffuse proliferative glomerulonephritis with extensive crescent formation in greater than 50% of glomeruli
<b>Antiglomerular basement membrane disease</b>	Rapidly progressive glomerulonephritis, nephritic syndrome	A focal segmental glomerulonephritis with necrosis which rapidly progresses to widespread crescent formation caused by antibodies to type IV collagen
<b>Type I MCGN, idiopathic. In association with infective endocarditis, visceral abscesses, infected arteriovenous shunts</b>	Nephritic syndrome <b>Nephrotic syndrome, haematuria, proteinuria</b>	A mesangiocapillary glomerulonephritis with intense cellular proliferation involving mesangial expansion and thickening of capillary walls due to extension of proliferation into capillary loops. Probably provoked by subendothelial immune complex deposition
<b>Hepatitis C associated type I MCGN</b>		May have additional intracapillary cryoglobulin deposition
<b>Type II MCGN (sometimes seen in association with partial lipodystrophy)</b>		Intense mesangial cell proliferation as above in the absence of immune complex deposition but in association with dense intramembranous deposits
<b>Systemic lupus erythematosus</b>	Nephritic syndrome, nephrotic syndrome, haematuria, proteinuria	WHO type III A focal proliferative glomerulonephritis involving cellular proliferation in mesangial and endocapillary areas affecting <50% of glomeruli WHO type IV A diffuse proliferative glomerulonephritis involving mesangial and endocapillary proliferation in >50% of glomeruli sometimes in association with necrosis and crescent formation

Patients with HSP also have systemic IgA containing immune complexes, though their size is larger than those in IgA disease. Mesangial deposition of IgA is usually seen but capillary wall staining for IgA is also frequent. Glomerular crescents and fibrin deposition are more common in HSP, as is capillary necrosis and leucocytoclastic vasculitis.<sup>9</sup> It is thought that subtle differences in the IgA complexes in HSP lead to greater leucocyte stimulation and thus to the small vessel vasculitis and extrarenal manifestations that define HSP.

### RAPIDLY PROGRESSIVE GLOMERULONEPHRITIS (RPGN)

The rapidly progressive glomerulonephritides are the most serious of all glomerulonephritides with the potential to

destroy renal function within days. Although causes are heterogeneous, they are united by the histological finding of extensive crescents (a proliferation of parietal epithelial cells and mononuclear phagocytes with possible fibroblasts in Bowman's capsule) affecting more than 50% of glomeruli. Causes fall into three broad categories with different presentations, treatments, and prognoses.

Pauci-immune glomerulonephritis caused by small vessel vasculitides accounts for about 50% of RPGN with an incidence of approximately 2 per 100 000 per year and a peak in the sixth decade with equal sex distribution. Disease may be limited to the kidney (idiopathic crescentic glomerulonephritis) or be associated with widespread systemic inflammation (Wegener's granulomatosis and microscopic polyangiitis). Overt presentation is often preceded by weight loss

**Table 2** Clinical features of acute glomerulonephritides

Type of glomerulonephritis	Age and sex	Investigations	Extrarenal manifestations
Post-infectious glomerulonephritis (post-streptococcal glomerulonephritis) IgA nephropathy	Most common between 2 and 12 years; boys > girls	Low C3 (alternative complement pathway), antistreptolysin titre	Sore throat or skin infection 7 days to 12 weeks before presentation
Henoch-Schönlein purpura	Commonly presents in 20s and 30s; men > women <20 years of age	Raised serum IgA in 50% of cases, complement normal Complement normal	Macroscopic haematuria may relate to time of infections Purpuric rash on legs, arthritis, abdominal pain
Wegener's granulomatosis, microscopic polyangiitis	50s/60s; men = women	ANCA, complement normal	Weight loss, malaise, upper and lower respiratory tract symptoms, arthritis, palpable purpura Lung haemorrhage especially in smokers
Antiglomerular basement membrane disease MCGN: Type I Type II Type I with hepatitis C	Young men; 50s and 60s; both sexes 20s; women > men teenage; women > men Middle age	Antiglomerular basement membrane antibody, complement levels normal Low C4 (classical path activation) Low C3 (alternative path activation), C3 nephritic factor Low C4, +ve hepatitis C serology, hepatitis C RNA on polymerase chain reaction, serum cryoglobulins, +ve antinuclear antibody/ +ve Rh factor Low C3, antinuclear antibody/ anti-ds DNA, anticardiolipin antibody	Lung haemorrhage especially in smokers Gaunt face due to partial lipodystrophy Abnormal liver function tests (rarely cirrhosis), purpuric rash, neuropathy, polyarthralgia, leg ulcers
Lupus nephritis	Young women in 20 and 30s	Low C3, antinuclear antibody/ anti-ds DNA, anticardiolipin antibody	Arthralgia, photosensitive skin rash, pleurisy, and pericarditis

and general malaise with later features relating to individual illnesses. Microscopic polyangiitis has cutaneous (palpable purpura), neurological (mononeuritis multiplex) or gastrointestinal vasculitis as well as renal failure, with pulmonary symptoms in only 50% of cases (due to non-granulomatous arteriolar vasculitis and capillaritis). By contrast, Wegener's granulomatosis is dominated by pulmonary manifestations with upper (deafness, nasal cartilage collapse, sinusitis), and lower (pulmonary haemorrhage due to granulomatous vasculitis) respiratory tract involvement and cavitating lung lesions seen on radiography.

Biopsy shows a focal or diffuse proliferative glomerulonephritis with extensive crescents. The pathogenesis of vasculitis remains the focus of much research but direct immunoglobulin deposition in the glomerulus is not thought to play a significant part (hence the term pauci-immune). Serologically, however, these diseases are linked in about 90% of cases by the finding of antineutrophil cytoplasmic antibodies (ANCA). Antibody staining is usually directed against the neutrophil cytoplasm in Wegener's with an antigen specificity for proteinase 3 on ELISA, whereas in microscopic polyangiitis it is generally perinuclear in pattern and is directed against myeloperoxidase. A direct causative role for ANCA in small vessel vasculitis remains controversial with experimental evidence pointing towards roles for neutrophils, macrophages, and T-cells in its pathogenesis.<sup>15</sup>

Antiglomerular basement membrane disease accounts for 10%–20% of cases of RPGN with a frequency of 0.5 cases per million per year in a European caucasoid population.<sup>2</sup> The disease occurs in two peaks, one in the third decade with a male preponderance and the second in the sixth and seventh decades affecting both sexes equally.<sup>16</sup> Associated lung involvement is more common in young men (when the disease is known as Goodpasture's disease), while that isolated to the kidneys is commoner in older patients. A prodrome of weight loss and malaise is less common than in the vasculitides and patients often present with either acute renal failure or haemoptysis due to lung involvement.<sup>17</sup> Haemoptysis is commoner in smokers and in those with fluid overload or intercurrent infections (the later also making the kidney damage more severe). Lung haemorrhage is the most common cause of death during early disease and should be suspected with haemoptysis or where a chest radiograph shows alveolar shadowing without restriction by anatomical fissures and with sparing of the upper zones. Acute

haemorrhage may be confirmed by a transiently raised transfer factor on pulmonary function testing.

Antiglomerular basement membrane disease is caused by antibodies that bind the alpha 3 chain of type 4 collagen found in the specialised basement membranes of the kidney and lung.<sup>18</sup> Initially histology may show a focal segmental glomerulonephritis with necrosis and interstitial inflammation but will rapidly progress to show widespread crescent formation with all crescents at the same stage of evolution (a previously normal kidney can develop 100% crescents in as little as five days). Immunofluorescence shows the linear deposition of IgG antibodies (sometimes associated with C3) along the glomerular basement membrane. Serology is positive for antiglomerular basement membrane antibodies but in 20%–30% of patients ANCA antibodies are also detected.<sup>19</sup> These latter patients behave clinically more like those with vasculitis (with lethargy, malaise, weight loss) and have a better renal prognosis than those with antiglomerular basement membrane antibodies alone—this may be because they are actually affected by vasculitis with the antiglomerular basement membrane antibodies being a secondary response to the damaged basement membrane.

Some 30%–40% of RPGN is due to a group of heterogeneous conditions where renal damage is associated with immune complex deposition or other causes of basement membrane damage such as accelerated hypertension. Pathology is frequently an aggressive variant of a glomerulonephritis normally associated with a more benign course (such as post-streptococcal glomerulonephritis, or IgA nephropathy), with histology being complicated by extensive inflammation and crescent formation. It is also seen after infections such as endocarditis and shunt nephritis or in association with multi-system disease such as systemic lupus erythematosus.

### MESANGIOCAPILLARY GLOMERULONEPHRITIS; ALSO KNOWN AS MEMBRANOPROLIFERATIVE GLOMERULONEPHRITIS

This rare form of glomerulonephritis has enjoyed renewed interest after the discovery that a subtype of MCGN type I is associated with chronic hepatitis C infection. MCGN commonly presents as a nephrotic syndrome but in 16%–30% of patients the initial presentation is with acute nephritis. The disease can be subdivided into types I and II, with its idiopathic forms mostly seen in children and young adults with cases presenting at a younger age in type II (15 years ± 11

years) than in type I (24 years  $\pm$  16 years) disease, with a slight female preponderance. Type I MCGN shares some features with lupus nephritis, and a similar histological picture can also be seen with endocarditis and infected arteriovenous shunts. In type II MCGN, patients may have an associated partial lipodystrophy giving them a very gaunt facial appearance.

It has recently been realised that a significant proportion of cases of type I MCGN previously labelled as idiopathic in fact occur in association with chronic hepatitis C infection<sup>20</sup> of which 20%–25% will present with acute nephritis.<sup>21</sup> There is geographical variation in this association and while hepatitis C associated renal disease appears particularly common in Japan (where the infection is found in up to 60% of cases of membranoproliferative glomerulonephritis) and Italy, it is less common in the USA (10%–20% of cases of membranoproliferative glomerulonephritis) and has been seen relatively little in France.<sup>20, 21</sup> Patients present 10–15 years after infection in middle age and have subclinical liver disease with mild biochemical abnormalities. Renal disease is often seen in the context of cryoglobulinaemia (cold precipitable mixed immunoglobulins composed of monoclonal IgM rheumatoid factor and polyclonal IgG). Patients suffer malaise, anaemia, peripheral neuropathy, polyarthralgia, and a purpuric rash together with lower limb ulceration and Raynaud's disease. Rarely vasculitis also affects the gastrointestinal or cardiological systems.<sup>22</sup>

Idiopathic type I MCGN is associated with activation of the classical complement pathway (and therefore with low C4 concentrations) while in MCGN type II alternative pathway activation is seen with low C3 and the presence of the C3 nephritic factor (an antibody leading to permanent activation of the complement cascade). In hepatitis C associated MCGN in addition to low classical complement component levels, patients have positive antihepatitis C antibodies and hepatitis C RNA on polymerase chain reaction. They may also have a positive antinuclear antibody and rheumatoid factor tests (70%) and positive cryoglobulins (75%).<sup>23</sup>

The pathogenesis of MCGN is obscure but probably involves intense cellular proliferation particularly involving mesangial cells. Histologically both types show mesangial expansion and thickening of the capillary walls (with reduction in the capillary lumina), which in the case of MCGN type I is partly due to cellular proliferation extending between the capillary basement membranes causing thickening and giving the classic tramline effect. Mesangial and capillary loop deposition of C3 occurs in both forms of MCGN but is accompanied by immunoglobulin deposition only in type I MCGN. The distinction between the different types is based on electron microscopy findings: in type I subendothelial immune deposits are seen in the glomerular basement membrane while in type II dense intramembranous deposits are seen in glomerular, tubular, and vascular basement membranes (the nature of these deposits in type II disease remains unknown but does explain its alternative name of dense deposit disease). In hepatitis C associated type I MCGN intracapillary deposits are thought to be due to precipitation of the cryoglobulins themselves.

## LUPUS NEPHRITIS

Renal involvement in systemic lupus erythematosus can present with proteinuria, haematuria, nephrotic syndrome, or with an acute nephritis. It is rarely the first manifestation of systemic lupus but usually occurs within five years and may be the first presentation leading to a definitive diagnosis.<sup>24</sup> Patients (most commonly women in their 20s and 30s with a black preponderance) will frequently have suffered lethargy, arthralgia or arthritis, skin rashes, and the symptoms of pleurisy and pericarditis in the months before presentation.<sup>25</sup> More than any other glomerulonephritis, lupus nephritis can change and evolve over time so that in a patient with an

initially benign glomerular lesion, a new presentation with acute glomerulonephritis should prompt repeat biopsy and if needed more aggressive treatment. High titres of antinuclear antibodies and antidouble stranded DNA antibodies together with low complement levels are helpful in a nephritic flare, although changes in such markers often precede the actual glomerular inflammation, sometimes by months.<sup>26</sup>

The pathology is at least in part that of immune complex deposition, with antigen antibody complexes forming systemically or in situ and subsequently activating the inflammatory cascade. Positively charged nuclear histone antigens can also bind to the glomerular basement membrane altering function and permeability and acting as planted antigens that are then the target of anti-DNA antibodies.

Acute glomerulonephritis in lupus is seen in patients who have focal and diffuse proliferative glomerulonephritis—that is World Health Organisation (WHO) class III and IV lupus nephritis<sup>27</sup> (WHO class I (normal kidney) and WHO class II (mesangial proliferation) lupus nephritis do not present as acute glomerulonephritis). In class III lupus nephritis (focal proliferative glomerulonephritis) there is proliferation in the mesangial and endocapillary areas in less than 50% of glomeruli. Such patients have haematuria and proteinuria and are sometimes nephritic. More commonly nephritic syndrome and renal impairment is associated with the more aggressive class IV diffuse proliferative glomerulonephritis where mesangial and endocapillary hypercellularity affect more than 50% of glomeruli with additional necrosis and possibly crescent formation. Subendothelial deposits give thickened basement membrane with a wire loop appearance on light microscopy. Immunofluorescence shows extensive granular deposition of IgG, IgA, IgM, and complement in subendothelial and mesangial areas.

## TREATMENT OF GLOMERULONEPHRITIS

The treatment of acute glomerulonephritis falls into two categories. Supportive treatment such as blood pressure control and dialysis is immediate and frequently life saving, but does not attempt to reverse the underlying pathology. Specific treatments aim to prevent and reverse glomerular inflammation and ultimately to preserve renal function—such treatments are often highly toxic and rely on non-specific suppression of the entire immune system. They carry the immediate risks of overwhelming infection and the later risk of reproductive toxicity and malignancy. In choosing such therapies, we need to select patients in whom kidney recovery is unlikely to occur spontaneously but where toxicity can be justified by the potential reversibility of the condition. On this basis we discuss current therapies and where possible present the rationale for their use (table 3). Many of these treatments together with newer therapies are the subject of ongoing clinical trials to determine optimum strategies.

The importance of supportive therapies in acute glomerulonephritis cannot be over emphasised. Tight blood pressure control, appropriate use of diuretics, and control of hyperkalaemia, uraemia and fluid overload, if necessary by dialysis, are quite literally life saving. Blood pressure control is vital not just in the short term but also later for any patient left with even mild renal impairment or proteinuria, with angiotensin converting enzyme (ACE) inhibitors having a particular place for their additional antiproteinuric and antifibrotic effects.<sup>28</sup>

In most cases of post-streptococcal glomerulonephritis where inflammation does resolve spontaneously, supportive therapies alone will be sufficient with improved renal function being seen between four and 14 days after the initial acute failure in 95% of patients.<sup>29</sup> Serum creatinine generally returns to baseline levels by four weeks but haematuria may persist for six months and mild proteinuria may be present in a few patients even at 10 years.<sup>30</sup> Rarely haematuria and proteinuria persist long term and are accompanied by hypertension and

**Table 3** Treatment of glomerulonephritis (treatments used widely in clinical practice are in bold type while newer therapies are in normal type)

Glomerulonephritis	Specific treatments used	Rationale for treatment
<b>Endocapillary glomerulonephritis</b> <b>Mesangioproliferative glomerulonephritis</b>	None required	Inflammation generally self resolving
<b>Antiglomerular basement membrane disease</b>	<b>Acute nephritic phase:</b> <b>Blood pressure control with ACE inhibitors</b> Pulsed intravenous steroids, cyclophosphamide, mycophenolate mofetil intravenous immunoglobulin <b>Pulsed intravenous steroids 1 g for 3/7 followed by oral steroids (60 mg/day)</b> <b>Cyclophosphamide orally (2–3 mg/kg/day)</b> <b>Plasma exchange (daily for 14 days or until no anti-GBM antibody)</b>	Reduce inflammation especially where renal function declining and crescents present To switch off antiglomerular basement membrane antibody production To remove existing antiglomerular basement membrane antibody while immunosuppression takes effect
<b>ANCA positive vasculitis</b>	<b>Pulsed intravenous steroids 1 g for 3/7 + oral steroids (start 60 mg), cyclophosphamide (2 mg/kg/day orally or 0.5–1 g monthly intravenous)</b> Plasma exchange ? for creatinine >500 or pulmonary haemorrhage	Suppression of antibody and cellular immune arms Removal of ANCA/immune complexes? Removal of proinflammatory cytokines?
<b>Immune complex-mediated RPGN</b>	Treat underlying histological variant If idiopathic as for ANCA positive vasculitis	Suppression of antibody response
<b>MCGN type I: idiopathic</b>	Steroids 40 mg/m <sup>2</sup> alternate days in children only Aspirin (325 mg/day) Dipyridamole (75–100 mg three times a day) in adults only	As antiplatelet agents to decrease cellular proliferation
<b>Type I: hepatitis C related</b>	Alpha-interferon/ribavirin Steroids, cyclophosphamide (plasma exchange)	To lessen viral drive To treat inflammatory component
<b>Type II</b>	No specific therapy shown to be helpful	
<b>Lupus nephritis</b>	<b>Intravenous steroids + oral steroids</b> <b>Intravenous/oral cyclophosphamide</b> Mycophenolate mofetil, cyclosporin	To suppress antibody production and reduce immune complexes

declining renal function.<sup>31</sup> For most other causes of glomerulonephritis however, if renal function is to be preserved, we must aim to reverse the underlying events causing glomerular inflammation.

The exact immunological events of IgA nephropathy are unknown and therefore treatment of IgA nephropathy is extremely difficult. For patients who present acutely with macroscopic haematuria, but with normal renal function and blood pressure, regular review alone may be all that is required. For patients who follow a more accelerated clinical course, once again control of blood pressure and careful fluid management are vital. Acute inflammation on biopsy may justify the use of immunosuppressives with anecdotal reports of success with mycophenolate mofetil, cyclophosphamide and pulsed steroids, and intravenous immunoglobulin.<sup>32–34</sup> In the more chronic phase, use of ACE inhibitors, both in hypertensive and in non-hypertensive patients who have proteinuria (>1 g/24 hours), is emerging as increasingly important. These drugs both reduce the level of proteinuria and slow the decline in glomerular filtration rate normally seen.<sup>35</sup>

Prognosis is difficult to estimate for those patients presenting acutely with IgA nephropathy. Certainly hypertension, impaired renal function, and severe proteinuria at presentation are adverse prognostic features<sup>36</sup> with one study suggesting that a combination of a raised creatinine (>150 µmol/l) together with proteinuria (>1 g/24 hours) gave a patient only a 20% chance of independent renal function seven years

later.<sup>12</sup> In HSP clinical presentation predicts prognosis with 15% of nephritic patients eventually reaching end stage renal failure, but up to 50% of those with a combined nephritic and nephrotic picture eventually needing renal replacement therapy.<sup>37</sup>

Rapidly progressive glomerulonephritis can irreversibly destroy renal function within days without treatment. Such risks therefore justify the use of significantly toxic therapies in an attempt to preserve independent renal function. In antiglomerular basement membrane disease, high dose steroids and cyclophosphamide are used to switch off B-cell production of antiglomerular basement membrane antibody with additional plasma exchange to remove existing antibody during the two weeks before the effects of cyclophosphamide as seen. In renal vasculitis (Wegener's and microscopic polyangiitis) much less is known of the pathogenesis but similar regimens aim to switch off both T-cell and B-cell function.<sup>38</sup>

Unless treatment is prompt, the renal prognosis in antiglomerular basement membrane disease is poor with few patients presenting with a serum creatinine greater than 600 µmol/l and requiring dialysis ever regaining independent renal function.<sup>39</sup> With plasma exchange and aggressive cytotoxic treatment, 80% of patients with a creatinine less than 600 µmol/l can expect improvements in renal function,<sup>2</sup> which are generally seen within days of starting treatment. Plasma exchange may be used even in those with irretrievably

damaged kidneys in an attempt to treat pulmonary haemorrhage.<sup>40</sup>

The prognosis in ANCA positive RPGN is better than that in anti-glomerular basement membrane disease. With aggressive treatment using steroids, cyclophosphamide, and plasma exchange at least five times if they are dialysis dependent, even 75% of those patients initially requiring renal support may recover renal function, with 80% of these remaining dialysis independent at five years.<sup>41</sup> Plasma exchange is also used in ANCA positive vasculitis associated pulmonary haemorrhage.<sup>42</sup> Recent trial data have confirmed that, after initial induction with steroids and cyclophosphamide for three months, many of these patients may be safely converted to an oral azathioprine regimen.<sup>43</sup>

The prognosis in immune complex RPGN is determined by the level of glomerular inflammation and treatment is directed at underlying pathology. The few cases of truly idiopathic immune complex RPGN appear to take a similar clinical course to pauci-immune RPGN and immunosuppressive regimens similar to those used in ANCA positive disease may be appropriate.

The pathology of idiopathic MCGN remains obscure and with little specific treatment of proven value, the importance of blood pressure control increases. In an attempt to limit the platelet activation associated with cellular proliferation, aspirin and dipyridamole have been used with some success and there may be a place for steroid treatment in children.<sup>44</sup> Type II MCGN is rare and shows little response to conventional therapies. Renal prognosis in truly idiopathic MCGN type I gives a 60% renal survival at 10 years; this figure is probably worse in MCGN type II.

Treatment of MCGN with hepatitis C infection is complex. If the disease is thought to be driven by virus-containing immune complexes, then control of viral load using alpha-interferon and ribavirin should be most effective—although this has shown some success with improvements in mild MCGN, relapse of viral load after stopping treatment is often seen.<sup>22</sup> Alternatively, where renal damage is more severe, the inflammatory component of the lesion might best be controlled with immunosuppressives albeit at a risk of viral activation. Some nephrologists would therefore treat an aggressive nephritic flare with pulsed methylprednisolone followed by 3–6 months of tapered oral steroids. Where disease is particularly active oral cyclophosphamide for two months has been used. With such treatments of cryoglobulinaemic vasculitis, extrarenal manifestations respond very quickly and in more than 85% of patients the plasma creatinine falls within a week, although proteinuria is much slower to respond. Long term immunosuppression is not justified and plasma exchange remains controversial.<sup>22</sup> Approximately 10% of patients with hepatitis C related kidney disease will develop end stage renal failure.<sup>21</sup>

The treatment of lupus nephritis is also complex with only part of its pathology being understood. As a disease that often strikes young women, the risks of renal disease must be weighed against possible infertility associated with immunosuppressive regimens. Renal biopsy is vital since, with an acute nephritic flare, it is important to distinguish scarred and irreversibly damaged kidneys from those that might benefit from aggressive immunosuppression. A recent study of patients with type IV lupus nephritis suggested that a combination of pulsed monthly methylprednisolone and intravenous cyclophosphamide resulted in a remission rate of approximately 85%.<sup>45</sup> Further quarterly doses of pulsed cyclophosphamide after the six months of monthly induction therapy also reduced the subsequent relapse rate. There may also be a place for intravenous immunoglobulin (working by solubilising immune complexes or blocking Fc receptors to prevent the inflammatory cascade) in refractory cases or mycophenolate mofetil in acute flares.<sup>46</sup> The most recent data suggest that with current treatment 70%–85% of patients with type III and

### Key references

- Hricik DE, Chung-Park M, Sedor JR. Glomerulonephritis. *N Engl J Med* 1998;**339**:888–99.
- Couser WG. Glomerulonephritis. *Lancet* 1999;**353**:1509–15.
- Madaio MP, Harrington JT. The diagnosis of glomerular diseases: acute glomerulonephritis and the nephrotic syndrome. *Arch Intern Med* 2001;**161**:25–34.
- Ruggenti P, Schieppati A, Remuzzi G. Progression, remission, regression of chronic renal diseases. *Lancet* 2001;**357**:1601–7.

### Sources of further information

- National Kidney Federation at [www.kidney.org.uk](http://www.kidney.org.uk) produces very helpful patient leaflets on glomerulonephritis, IgA nephropathy, and mesangiocapillary glomerulonephritis.
- Arthritis Research Campaign at [www.arc.org.uk](http://www.arc.org.uk) produces excellent patient leaflets on lupus and vasculitis.

IV lupus nephritis will retain independent renal function at five years. Repeated acute nephritic flares are a poor prognostic indicator, as are hypertension and black race.

Glomerulonephritis is an important cause of renal failure for which we currently have only non-specific and potentially toxic therapies. With increasingly prompt diagnosis and greater understanding of pathology, we must hope to improve this situation. As knowledge grows, we may prevent some glomerulonephritides altogether, for instance by successful vaccination against hepatitis C for MCGN or by designing therapies to reverse immune complex formation in systemic lupus erythematosus. For patients in whom glomerulonephritis does occur, drugs may be designed which tackle inflammation by interrupting the complement or cytokine cascades or which target the cell signalling that leads to proliferation and subsequent fibrosis. Only then can we hope to prevent the many cases of chronic renal failure caused by these diseases.

### SELF TEST QUESTIONS ON ACUTE GLOMERULONEPHRITIS (ANSWERS AT END OF REFERENCES)

- Q1. What is the most likely diagnosis in a 15 year old boy presenting to casualty with a sore throat and macroscopic haematuria?
- Q2. Which of the following statements about lupus nephritis are true?
- (A) Patients with lupus nephritis may have a normal serum creatinine value
- (B) Patients with lupus nephritis may require multiple sequential biopsies
- (C) In lupus nephritis a fall in C3 levels and a rise in antidouble stranded DNA levels may precede actual glomerular inflammation
- (D) Patients with lupus nephritis often develop infertility as a result of their treatment
- Q3. Plasma exchange is a recognised treatment in which of the following forms of glomerulonephritis?
- (A) Lupus nephritis
- (B) Anti-glomerular basement membrane disease
- (C) ANCA positive vasculitis
- (D) IgA nephropathy

Q4. Immune complex deposition is thought to be important in the pathogenesis of which of the following forms of glomerulonephritis?

- (A) Lupus nephritis
- (B) IgA nephropathy
- (C) ANCA positive vasculitis
- (D) MCGN type II

Q5. Which of the following diseases, which can present as an acute nephritic syndrome, also commonly present with a nephrotic picture?

- (A) Lupus nephritis
- (B) IgA nephropathy
- (C) Antiglomerular basement membrane disease
- (D) Mesangioproliferative glomerulonephritis
- (E) Post-streptococcal glomerulonephritis

#### Authors' affiliations

C S Vinen, D B G Oliveira, Department of Renal Medicine, St. George's Hospital Medical School, London

#### REFERENCES

- 1 **US Renal Data Systems.** *USRDS 1997 annual data report.* Bethesda: National Institute of Health, National Institute of Diabetes and Digestive and Kidney Diseases, April 1997.
- 2 **Kluth DC, Rees AJ.** Anti-glomerular basement membrane disease. *J Am Soc Nephrol* 1999;**10**:2446–53.
- 3 **Oliveira DBG.** Poststreptococcal glomerulonephritis: getting to know an old enemy. *Clin Exp Immunol* 1997;**107**:8–10.
- 4 **Hricik DE, Chung-Park M, Sedor JR.** Glomerulonephritis. *N Engl J Med* 1998;**339**:888–99.
- 5 **Couser WG.** Glomerulonephritis. *Lancet* 1999;**353**:1509–15.
- 6 **Tejani A, Ingulli E.** Poststreptococcal glomerulonephritis: current clinical and pathological concepts. *Nephron* 1990;**55**:1–5.
- 7 **Peake PW, Pussell BA, Karpus TE, et al.** Post-streptococcal glomerulonephritis: studies on the interaction between nephritis strain-associated protein (NSAP), complement and the glomerulus. *APMIS* 1991;**99**:460–6.
- 8 **Johnson RJ, Lovette D, Lehrer RJ, et al.** Role of oxidants and proteases in the glomerular injury. *Kidney Int* 1994;**45**:352–9.
- 9 **Davin J-C, Ten Berge IJ, Weeing JJ.** What is the difference between IgA nephropathy and Henoch Schönlein purpura nephritis? *Kidney Int* 2001;**59**:823–34.
- 10 **Emancipator SN.** IgA nephropathy: morphological expression and pathogenesis. *Am J Kidney Dis* 1994;**23**:451–62.
- 11 **Galla JH.** IgA nephropathy. *Kidney Int* 1995;**47**:377–87.
- 12 **Floege J, Feehally J.** IgA nephropathy: recent developments. *J Am Soc Nephrol* 2000;**11**:2395–403.
- 13 **D'Amico G.** Clinical features and natural history in adults with IgA nephropathy. *Am J Kidney Dis* 1988;**12**:353–7.
- 14 **Kaku Y, Nohara K, Honda S.** Renal involvement in Henoch Schönlein purpura: a multivariate analysis of prognostic factors. *Kidney Int* 1998;**53**:1755–9.
- 15 **Tippling PG, Kitching AR, Cunningham MA, et al.** Immunopathogenesis of crescentic glomerulonephritis. *Curr Opin Nephrol Hypertens* 1999;**8**:281–6.
- 16 **Merkel F, Pullig O, Marx M, et al.** Course and prognosis of anti-basement membrane antibody mediated disease: report of 35 cases. *Nephrol Dial Transplant* 1994;**9**:372–6.
- 17 **Donaghy M, Rees AJ.** Cigarette smoking and lung haemorrhage in glomerulonephritis caused by autoantibodies to glomerular basement membrane. *Lancet* 1983;**ii**:1390–3.
- 18 **Kalluri R, Wilson CV, Weber M, et al.** Identification of the  $\alpha$ -3 chain of type IV collagen as the common autoantigen in anti-glomerular basement membrane disease and Goodpasture's syndrome. *J Am Soc Nephrol* 1995;**6**:1178–84.
- 19 **Jayne DR, Marshall PD, Jones SJ, et al.** Autoantibodies to GBM and neutrophil cytoplasm in rapidly progressive glomerulonephritis. *Kidney Int* 1990;**37**:965–70.
- 20 **Johnson RJ, Wilson R, Yamabe H, et al.** Renal manifestations of hepatitis C virus infection. *Kidney Int* 1994;**46**:1255–63.
- 21 **Daghestani L, Pomeroy C.** Renal manifestations of hepatitis C infection. *Am J Med* 1999;**106**:347–54.
- 22 **Campise M, Tarantino A.** Glomerulonephritis in mixed cryoglobulinaemia: what treatment? *Nephrol Dial Transplant* 1999;**14**:281–3.
- 23 **D'Amico G, Fornasieri A.** Cryoglobulinaemic glomerulonephritis: a membranoproliferative glomerulonephritis induced by hepatitis C virus. *Am J Kidney Dis* 1995;**25**:361–9.
- 24 **Baldwin DS, Gluck MC, Lowenstein J, et al.** Lupus nephritis: clinical course as related to morphological forms and their transitions. *Am J Med* 1977;**62**:12–30.
- 25 **Madaio MP, Harrington JT.** The diagnosis of glomerular diseases: acute glomerulonephritis and the nephrotic syndrome. *Arch Intern Med* 2001;**161**:25–34.
- 26 **Boumpas DT, Austin HA, Fessler BJ, et al.** Systemic lupus erythematosus: emerging concepts. 1. Renal, neuropsychiatric, cardiovascular, pulmonary, and haematological disease. *Ann Intern Med* 1995;**122**:940–50.
- 27 **Kashgarian M.** Lupus nephritis: lessons from the path lab. *Kidney Int* 1994;**45**:928–38.
- 28 **Ruggenenti P, Schieppati A, Remuzzi G.** Progression, remission, regression of chronic renal diseases. *Lancet* 2001;**357**:1601–7.
- 29 **Lewy JE, Salinas-Madriral L, Herdson TB, et al.** Clinico-pathological correlations in acute post streptococcal glomerulonephritis: a correlation between renal function, morphological damage and clinical course of 46 children with acute post-streptococcal glomerulonephritis. *Medicine* 1971;**50**:453–71.
- 30 **Potter EV, Lipschultz SA, Abidh S, et al.** Twelve to seventeen year follow up of patients with post streptococcal acute glomerulonephritis in Trinidad. *N Engl J Med* 1982;**307**:725–9.
- 31 **Schact RG, Gluck MC, Gallo GR, et al.** Progression to uremia after remission of acute post streptococcal glomerulonephritis. *N Engl J Med* 1976;**295**:977–81.
- 32 **Nolin L, Corteau M.** Management of IgA nephropathy: evidence-based recommendations. *Kidney Int* 1999;**55**(suppl 70):S56–62.
- 33 **Nowack R, Birc R, van der Woude FJ.** Mycophenolate mofetil for systemic vasculitis and IgA nephropathy. *Lancet* 1997;**349**:774.
- 34 **McIntyre CW, Fluck RJ, Lambie SH.** Steroid and cyclophosphamide therapy for IgA nephropathy associated with crescentic changes: an effective treatment. *Clin Nephrol* 2001;**56**:193–8.
- 35 **Catran DC, Greenwood C, Ritchie S.** Long term benefit of angiotensin-converting enzyme inhibitor therapy in patients with severe immunoglobulin A nephropathy: a comparison to patients receiving treatment with other hypertensive agents and to patients receiving no therapy. *Am J Kidney Dis* 1994;**23**:247–54.
- 36 **D'Amico G.** Natural history of idiopathic IgA nephropathy: role of clinical and histological prognostic factors. *Am J Kidney Dis* 2000;**36**:227–37.
- 37 **Goldstein AR, White RHR, Akuse R, et al.** Long-term follow-up of childhood Henoch Schönlein nephritis. *Lancet* 1992;**339**:280–2.
- 38 **Jindal KK.** Management of idiopathic crescentic and diffuse proliferative glomerulonephritis: evidence-based recommendations. *Kidney Int* 1999;**55**(suppl 70):S33–40.
- 39 **Mokrzycki MH, Kaplan AA.** Therapeutic plasma exchange: complications and management. *Am J Kidney Dis* 1994;**23**:817–27.
- 40 **Levy JB, Pusey CD.** Still a role for plasma exchange in rapidly progressive glomerulonephritis. *J Nephrol* 1997;**10**:7–13.
- 41 **Gaskin G, Pusey CD.** Long term outcome after immunosuppression and plasma exchange for severe vasculitis associated with glomerulonephritis. *J Am Soc Nephrol* 1999;**10**:101A.
- 42 **Levy J.** New aspects in the management of ANCA-positive vasculitis. *Nephrol Dial Transplant* 2001;**16**:1314–17.
- 43 **Jayne D, Rasmussen N.** European collaborative trials in vasculitis: EUVAS update and latest results. *Clin Exp Immunol* 2000;**20**(suppl 1):13–15.
- 44 **Levin A.** Management of membranoproliferative glomerulonephritis: evidence-based recommendations. *Kidney Int* 1999;**55**(suppl 70):41–6.
- 45 **Gourley MF, Austin HA, Scott D, et al.** Methylprednisolone and cyclophosphamide, alone or in combination, in patients with lupus nephritis. A randomised controlled trial. *Ann Intern Med* 1996;**125**:549–57.
- 46 **Chan TM, Li FK, Tang CSO, et al.** Efficacy of mycophenolate mofetil in patients with diffuse proliferative lupus nephritis. *N Engl J Med* 2000;**343**:1156–62.

#### ANSWERS

Q1. IgA nephropathy. Q2. A, B, C. Q3. B, C. Q4. A, B. Q5. A, D.