warts) and verruca palmaris (palmar warts) are exophytic and endophytic papules with thrombosed capillaries manifesting as black dots when the top of the wart is pared down.

Diagnosis is clinical. Warts are usually self-limited; however, in severe cases, including those with a protracted course or in persons who are immunocompromised, destructive treatments can be used. Location of the lesions must be taken into account when selecting treatment, which can be associated with pigment change or scarring. Numerous treatments (salicylic acid, cryotherapy, tricarboxylic acid, cantharidin, podophyllin, and laser) focused on destroying infected keratinocytes are available. Other treatments, such as imiquimod and intralesional *Candida*, elicit a local immune response to eliminate the warts.

HPV vaccination is recommended for young persons to prevent cervical and anal carcinoma and should also serve to decrease anogenital warts. See Routine Care of the Healthy Patient for more information.

Callus and Corns

A callus is a collection of thickened, hardened stratum corneum that presents as a flat papule or plaque at the site of repetitive trauma, frequently under bones. Sometimes the term corn is used interchangeably with callus; however, corns have more distinct edges, are more rounded, and have a central core that can be soft or hard. Corns are typically seen on the sides or tops of toes. Treatment involves mechanical or chemical paring with salicylic acid, but removing the pressure from the site is necessary to prevent repeated formation.

Acrochordon (Skin Tags)

Acrochordons (skin tags) are skin-colored, pedunculated papules (**Figure 108**). They are most commonly seen on the neck and skin folds in older adults and those with obesity and diabetes mellitus. Skin tags appear with increased frequency during the second trimester of pregnancy and may regress postpartum. Perianal skin tags are common in patients with Crohn disease. If lesions become necrotic or crusted, they may require removal with cryotherapy or snip excision. They can be of cosmetic concern, especially when numerous. The presence of numerous lesions, particularly in the setting of obesity and acanthosis nigricans, is associated with insulin resistance.

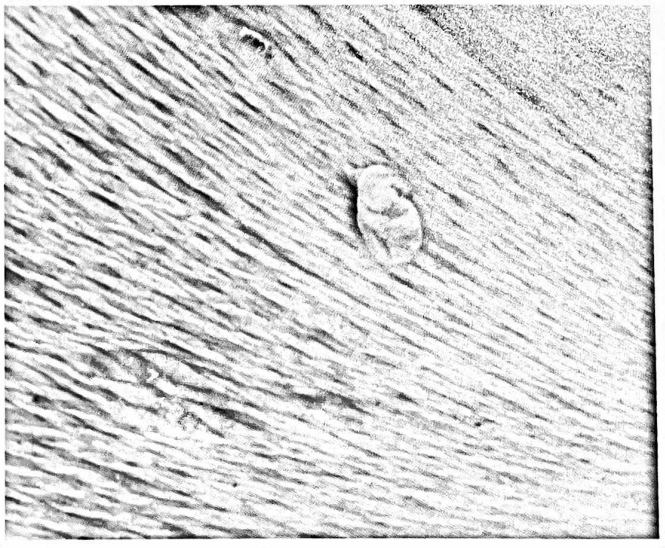

FIGURE 108. Acrochordons (skin tags) are skin-colored papules that arise on areas of friction, such as the neck, axillae, and groin.

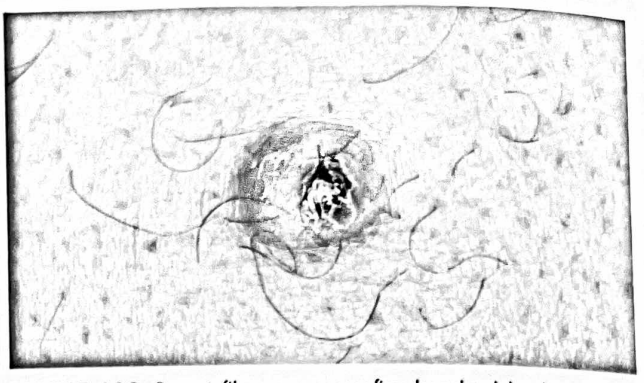

FIGURE 109. Dermatofibromas appear as firm dermal nodules about the size of a pencil eraser. They are frequently hyperpigmented or may have pigment at the periphery.

Dermatofibroma

Dermatofibromas are benign, fibrohistiocytic lesions that are common on the extremities, particularly the legs of young women. They are tan-to-brown discrete papules that often have a slightly darker brown ring encircling the main part of the lesion (**Figure 109**). Dermatofibromas are usually asymptomatic, and treatment is not necessary.

Nevi

Melanocytic nevi are benign neoplasms composed of melanocytes; they are commonly referred to as moles. They occur anywhere on the body, including the palms, soles, and mucous membranes. Melanocytic nevi can appear early in childhood and increase in number until middle age. They vary in clinical appearance depending on the location of melanocytes within the skin (**Table 85** and **Figure 110**). Clinically they can mimic melanoma, necessitating a biopsy for accurate diagnosis.

Halo nevi are melanocytic nevi with an admixed chronic lymphocytic infiltrate that signifies regression of the nevus.

TABLE 85. Types of Melanocytic Nevi

Type	Location of Melanocyte Nests in Skin	Clinical Appearance
Junctional melanocytic nevus	Dermal-epidermal junction	Brown-to-black macules
Compound melanocytic nevus	Dermal-epidermal junction and dermis	Tan-to-brown papules or nodules
Intradermal melanocytic nevus	Dermis	Tan-to-skin-colored papules

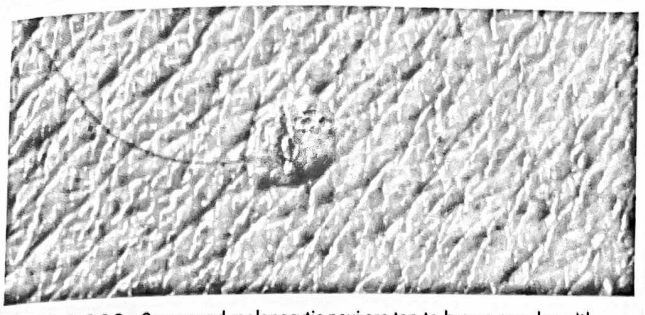

FIGURE 110. Compound melanocytic nevi are tan-to-brown papules with regular borders and even color.

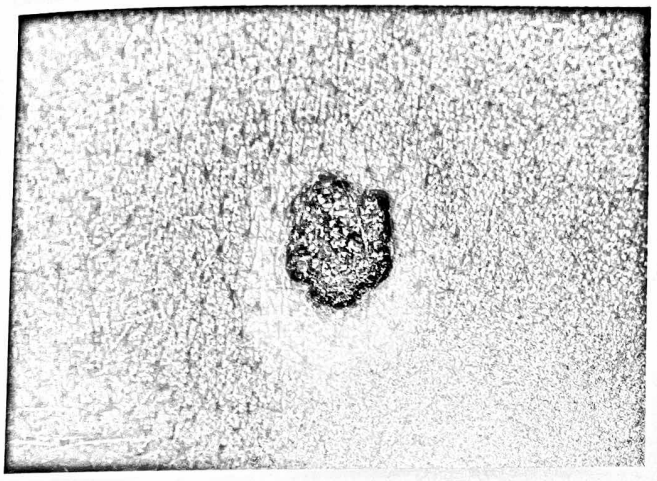

FIGURE 111. Halo nevus, with a depigmented halo surrounding a brown papule.

Halo nevi are central tan-to-brown macules or papules with a surrounding halo of hypopigmented or depigmented skin (**Figure 111**). They most frequently present on the back of teenagers or young adults. Multiple halo nevi have been associated with melanoma; therefore, these patients should have a complete skin examination to assess for concurrent lesions.

Dysplastic Nevi

Dysplastic (or atypical) nevi are melanocytic nevi that are often asymmetric and irregularly bordered, have multiple colors, and may be quite large in diameter. Dysplastic nevi are most commonly found on the trunk and extremities. Many have a "fried egg" appearance with an eccentric, dark brown papular center and surrounding light brown ring. Dysplastic nevi can display one or more of the identifying characteristics of melanoma, making an accurate clinical diagnosis impossible (see Melanoma). In cases of uncertainty, biopsy of the lesion can typically exclude melanoma; however, it is imperative to sample the entire lesion, including a 1- to 2-mm border of normal surrounding skin.

Although melanoma can arise within any melanocytic nevi, including dysplastic nevi, the risk for this occurring within any given lesion is quite small. Excisional biopsy is reserved for lesions that display features suggesting melanoma, are changing in size and color, are symptomatic, or stand out from the patient's other nevi. Patients with multiple dysplastic nevi are at risk for developing melanoma and should be monitored closely (**Figure 112**). Some of these patients have dysplastic nevus syndrome. Criteria for this syndrome include a history of melanoma in one or more first- or second-degree relatives, the presence of more than 50 nevi, multiple nevi with atypical clinical features, and multiple nevi with atypical histologic features. These patients are at increased risk for melanoma and should have yearly total-body skin examinations.

FIGURE 112. Dysplastic nevi are commonly larger than 6 mm and have irregular borders. This patient has numerous dysplastic nevi and is at increased risk for melanoma.

KEY POINTS

- Warts are usually self-limited and treatment unnecessary; however, in severe cases, including those with a protracted course or in persons who are immunocompromised, destructive treatments can be used. **HVC**
- Dysplastic nevi can display one or more of the identifying characteristics of melanoma; patients with multiple dysplastic nevi are at increased risk for melanoma and should be monitored closely.
- Excisional biopsy of dysplastic nevi is reserved for lesions that display features suggesting melanoma, are changing in size and color, are symptomatic, or stand out from the patient's other nevi. **HVC**

Premalignant and Malignant Tumors

Skin cancer is a major public health concern, and one in five people in the United States will develop it. Most cases are caused by excessive UV light exposure. People of all skin pigmentation can develop skin cancer, but fair-skinned persons are more susceptible to the effects of UV light exposure.

Actinic Keratosis

Actinic keratoses are precancerous lesions of the epidermis. Approximately 1% to 5% of actinic keratoses will develop into