

# Advanced Cardiac Imaging

BMC's Advanced Cardiac Imaging Program (ACIP) offers access to state-of-the-art computed tomography (CT), positron emission tomography/computed tomography (PET/CT), and magnetic resonance imaging (MRI) of the heart to patients and referring and community clinicians. The ACIP is a collaboration between the Section of Cardiovascular Medicine and the Department of Radiology, with faculty drawn from both departments. Working together, physicians bring expertise in cardiovascular patient care as well as in-depth knowledge of imaging techniques. This cooperative relationship is essential to the program's success. All studies are interpreted by physicians with advanced training in cardiac MR (CMR), cardiac CT, and/or cardiac PET/CT.

CMR affords clear and precise images of the heart in motion, without ionizing x-ray radiation, and free of interference from chest structures that can limit echocardiography. Exact quantification of heart chamber size, blood flow, and systolic function are routinely determined in every CMR examination. CMR also can directly image prior myocardial scarring (for example from myocardial infarction) or fibrosis so as to identify the mechanism of heart dysfunction. Thus, CMR is useful in any form of cardiomyopathy, or to clarify any unclear finding from echocardiography.

CT technology allows clinicians to non-invasively evaluate the coronary arteries and obtain diagnostic information similar to that acquired with invasive angiography (cardiac catheterization). Cardiac CT is of particular use in the exclusion of significant coronary artery disease and thus can replace a cardiac catheterization in appropriate patients. The American Heart Association recently stated that a heart CT is reasonable in patients with chest discomfort who are of intermediate cardiovascular risk and/or those with a prior

[Skip to Main Content](#)

non-diagnostic or equivocal stress test result. Heart CT should not, however, be used as a screening test in asymptomatic patients because of long-term radiation exposure concerns and lack of proven benefit.

Cardiac PET/CT enables a high-quality examination of cardiac perfusion and/or metabolism. Cardiac PET/CT perfusion studies use the radioisotope rubidium-82 and provide more accurate perfusion data than traditional nuclear stress tests that utilize technetium or thallium SPECT imaging. Rubidium-82 PET/CT studies are particularly useful in patients who are unable to exercise (require pharmacologic stress), are obese, or have a prior non-diagnostic cardiac stress test. In addition, rubidium-82 cardiac PET/CT exposes patients to significantly less radiation than traditional nuclear stress tests and can be performed, start-to-finish, in less than one hour. Cardiac PET/CT metabolic studies use  $^{18}\text{F}$ -fluorodeoxyglucose (FDG) to evaluate glucose uptake in the heart. Cardiac FDG PET/CT studies are used to determine if an area of heart muscle is living (viable) or is inflamed in conditions such as sarcoidosis.

In keeping with BMC's long tradition of being a leader in cutting-edge research and cardiac care, ACIP research physicians are currently studying the utility of CT in post-operative coronary bypass surgery patients, the utility of cardiac MR in various heart failure conditions, and testing novel contrast agents. BMC is also a participant in the National Institutes of Health sponsored PROMISE (PROspective Imaging Study for Evaluation of Chest Pain) trial of cardiac CT vs. standard exercise testing for outpatients with chest pain.

An increasing number of clinicians are utilizing the imaging capabilities offered by CMR, CTA, and PET/CT scans to expedite diagnosis and therapy. BMC's non-invasive cardiologists can assist community clinicians by placing these new techniques into a useful clinical context. For patients, these technologies offer faster diagnosis and timely therapy. For physicians, CTA, PET/CT, and CMR can afford improved confidence in diagnosis and fewer tests.

[Skip to Main Content](#)

**Cardiac MRI (CMR) offers the following diagnostic options:**

- Precise quantification of left ventricle and/or right ventricle size and/or function
- Assessment of myocardial viability after myocardial infarction
- Assessment of etiology of cardiomyopathy (ischemic, nonischemic, infiltrative, ARVD)
- Quantification of valvular regurgitation and/or intra-cardiac shunt
- Evaluation of cardiac masses
- Evaluation of pericardial disease, including constrictive pericarditis
- Clarification of abnormal or equivocal echo finding

### **Cardiac CT angiography (CTA) offers the following assessment tools:**

- Assessment of coronary artery anatomy in patients who are of intermediate cardiovascular risk profile and who have symptoms of chest discomfort
- Assessment of coronary artery anatomy in those with previous stress testing that is equivocal

### **Cardiac PET/CT offers the following diagnostic options:**

- Qualitative and quantitative assessment of myocardial perfusion
- Determination of left ventricular systolic function both at rest and stress, enabling measurement of 'ejection fraction reserve'
- Measurement of coronary calcium (Agatston Score)
- Examination of myocardial viability/hibernation
- Examination for cardiac sarcoidosis

Once the need for a cardiac MRI, PET/CT, or CTA has been determined by a requesting clinician, pre-authorization is required from the patient's health insurance company. Upon receiving pre-authorization from the health insurance company, please contact the ACIP directly.

**Contact Us**

[Skip to Main Content](#)

Call (617) 638-8745 to schedule a study or for more information.

Referring physicians with specific questions about cardiac CT or MRI may speak directly to a physician via the ACIP’s dedicated pager at (617) 638-5795, pager # 1176.

## **Our Team**

- Frederick Ruberg, MD, Director
- Stephan Anderson, MD
- Avneesh Gupta, MD
- Nagaraj Holalkere, MD
- Gustavo A. Mercier, Jr., MD, PhD
- Marcello Panagia, M.D., DPhil
- Jarry Tkcaz, MD
- Rajendran Vilvendhan, MD

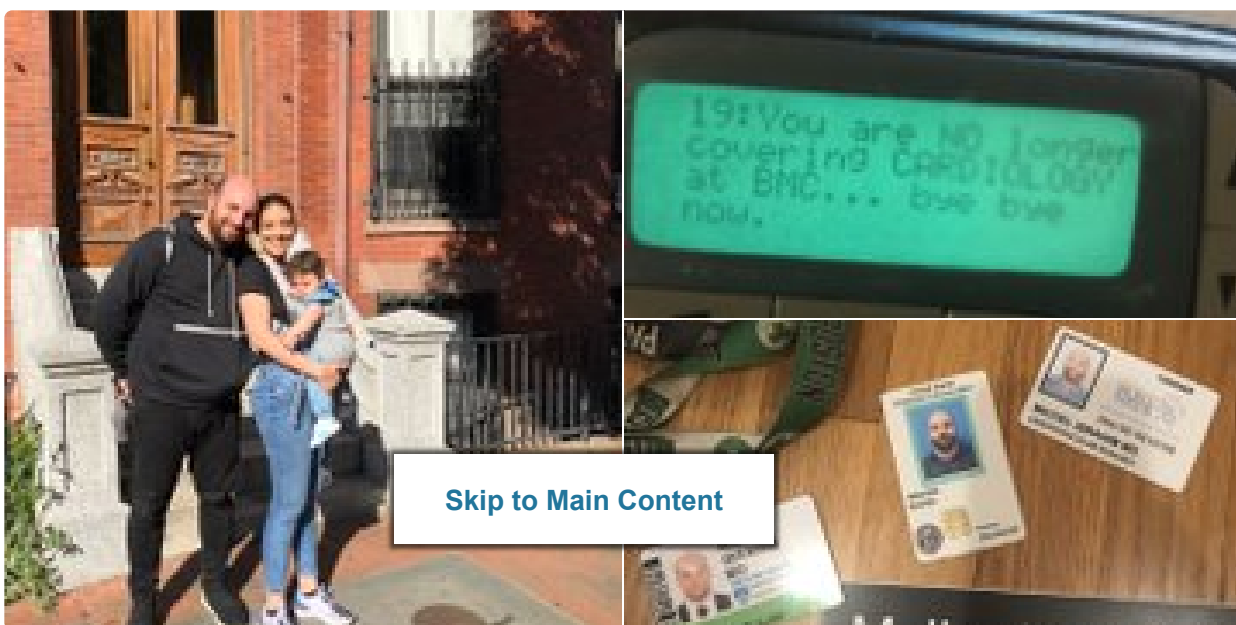
## **Tweets** by [@BUcards](#)

BMC|BU Cardiology Fellows Retweeted



**Michel Ibrahim, MD**  
[@DrMichellbrahim](#)

It’s been an honor to be part of such a historical institution [@BUcards](#) [@The\\_BMC](#) and to serve incredible patients. It was a pleasure to work with great individuals. Thank you [#BOSTON](#) for helping me and my family live our dreams. See you soon...



Jun 24, 2021